



Magnetic Resonance Imaging and Perfusion Computed Tomography in The Diagnosis of Ischemic Brain Damage

Djuraeva N.M., Amirkhamzaev A.T.

State Institution "Republican Specialized Scientific and Practical Medical Center for Surgery named after academician V.Vakhidov", Tashkent, Uzbekistan

ABSTRACT

To determine the relationship between functional changes in perfusion computed tomography (PCT) and structural changes detected in diffusion-weighted MRI (DWI-MRI) in patients with acute cerebral ischemia. The results of a survey of 48 primary patients (14 women and 34 men aged 25 to 75 years, mean age 47.4 ± 8.1 years) with ischemic stroke were analyzed (on average, 14 hours passed from the moment of stroke to PCT), which was confirmed by the results of DWI-MRI. The studies were carried out on a magnetic resonance tomograph (MRI) Signa Hdxet 1.5 Tesla and a wide detector 640 slice multislice computed tomography Aquilion One - 640 Genesis version (Toshiba Medical Systems, Japan). All 48 cases showed signs of cerebral infarction. The weighting factor was $b=1000$, the median area of the identified ischemic areas was 1125.7 ± 431.8 mm² (from 544.0 to 2214.0 mm²). When evaluating the correlation between the size of the focus of increased signal intensity on DWI-MRI and the area of the lesions on perfusion maps, i.e. when studying the relationship of initial structural changes with functional ones. The highest closeness of the correlation was noted for the cerebral blood volume (CBV) ($r=0.752$, $p<0.01$). Patients with a discrepancy between the size of the ischemic focus on PCT and the areas of the ischemic focus on DWI-MRI were identified. Also identified were 70.8% (34 of 48) of cases with penumbra on cerebral blood flow (CBF) and mean transit time (MTT), and no signal change on DWI-MRI. At the same time, cases with altered areas of CBF, CBV and MTT, and areas of change in diffusion on DWI-MRI were more among patients with penumbra ($p<0.001$). In patients with ischemic stroke, there is a comparison of cerebral perfusion parameters measured on PCT with MRI signs.

Keywords: acute cerebral stroke, diagnostics, perfusion computed tomography, magnetic resonance imaging, cerebral blood flow, cerebral blood volume, mean transit time

Received 14.07.2023

Revised 27.08.2023

Accepted 21.09.2023

INTRODUCTION

Despite the decline in the frequency of ischemic strokes over the past few decades, they remain the leading cause of death and disability worldwide [1-3]. The decrease in the incidence of ischemic stroke is directly related to both an improved understanding of prevention methods and optimization of methods of radiation diagnostics [4-6].

Stroke can be diagnosed using a number of methods, including neurological examination, computed tomography (CT), magnetic resonance imaging (MRI), ultrasound Dopplerography and arteriography. And despite the fact that various types of imaging methods have significantly advanced since their introduction, CT remains the most common and effectively used imaging method for both the diagnosis of acute ischemic stroke and for differentiation from hemorrhagic stroke due to lower cost, wide availability, fast speed, and accuracy compared to other basic methods visualizations [4, 5].

Perfusion computed tomography (PCT) is another useful imaging technique that can provide important information about the hemodynamics of the brain parenchyma at the capillary level [5, 6, 7].

MRI scanning allows doctors to obtain images of diffusion and perfusion, and it has been shown to be very useful for diagnosing acute ischemic stroke, while at the same time differentiating it from hemorrhagic strokes [8]. Diffusion-weighted imaging (DWI) is a method used on the basis of MRI, which has a higher sensitivity and accuracy for acute ischemic stroke, which became clear when compared with other imaging methods. DWI-MRI is sensitive to acute cellular damage in cerebral ischemia and can be used to assess ischemic lesions in the first few hours [8].

Despite the large amount of literature that analyzes various aspects of detection and treatment by various imaging methods, there is no comprehensive information about the diagnostic value of each of them and the correlation analysis of the obtained parameters.

The present study was aimed at comparing and establishing the relationship of diagnostic findings during CT and MRI in the diagnosis of acute ischemic stroke.

MATERIAL AND METHODS

The article presents the results of the examination of 48 primary patients (average age – 47.4 ± 8.1 years) with ischemic stroke with an already formed ischemic focus (on average, 14 hours passed from the moment of stroke development to PCT), which was confirmed by the results of DWI-MRI.

Thus, the study was aimed at determining the ratio of functional changes in PCT with structural changes detected by diffusion-weighted MRI (DWI-mode-MRI) of the brain.

All patients were examined in the State Institution "Republican Specialized Scientific and Practical Medical Center for Surgery named after academician V.Vakhidov" for the period from 2017-2022. The studies were carried out on a 1.5 tesla Signa Hdxet MR tomograph and a wide-detector 640 slice MSCT "Aquilion One - 640" version of Genesis (Toshiba Medical Systems, Japan).

The severity of the stroke was assessed on the stroke scale of the National Institutes of Health (NIHSS) and the Glasgow Coma Scale. The criteria of mild stroke severity were met by 32 (66.7%) patients without impaired consciousness, without a clinic of brain edema, with focal neurological symptoms (NIHSS score on day 1. < 8 points). The average severity of the clinical course of stroke with impaired consciousness (score on the NIHSS scale of 8-16 points, on the Glasgow scale of 11-14 points) was diagnosed in 18.8% (9 out of 48) cases. Severe stroke (NIHSS score on day 1. More than 16 points with impaired consciousness in the form of a sopor (9-10 points on the Glasgow scale) Coma (3-8 points on the Glasgow scale) was detected in the remaining 7 (14.6%) patients. On average, the severity of neurological deficit at admission was 11.5 points on the NIHSS scale (7.3–16.0 points).

CT perfusion was used to obtain information about the totality of the following parameters: cerebral blood volume (CBV) – the total volume of blood in the selected area of brain tissue; cerebral blood flow (CBF) – the rate of passage of a certain volume of blood through a given volume of brain tissue per unit of time; average transit time (mean transit time (MTT) is the average time for which blood passes through the vascular bed of the selected area of brain tissue, measured in seconds (s). According to the principle of central volume, which is common to all methods of evaluating tissue perfusion, these parameters are related by the ratio $CBV = CBF \times MTT$.

Multimodal CT protocol in acute stroke conditions included:

- contrast-free CT of the brain,
- CT angiography (CT) of the vessels of the head and neck,
- CT perfusion.

The multimodal MRI protocol for acute stroke included:

- DWI (foci of acute and acute ischemia),
- FLAIR (assessment of brain parenchyma, foci of ischemia > 6 hours old),
- gradient sequences SWI/SWAN or T2*-GRE (detection of microhemorrhagia and venous pathology),
- MR perfusion,
- MR angiography in 3D TOF mode.

RESULTS

Analysis of the obtained MRI results in DWI mode revealed signs of a cerebral infarction, i.e. areas with increased signaling intensity. The weighting factor was $b=1000$, the median area of the identified ischemia sites was 1125.7 ± 431.8 mm² (from 544.0 to 2214.0 mm²). DWI-MRI data showed that cases of medium-sized infarcts prevailed among patients (45.8%; 22 out of 48), a smaller proportion were small (5 out of 48; 10.4%) and large (18.8%; 9 out of 48) infarcts, and in a quarter of patients the focus of ischemia was extensive (25%; 12 of 48) (fig. 1).

By the time of PCT in the ischemic area, we observed a decrease in CBF and CBV along with an increase in MTT, which indicated a breakdown in autoregulation of cerebral circulation as a result of occlusion of the fetal vessel. Thus, the picture of perfusion changes observed by us corresponded to the existing ideas about the pathophysiological processes characteristic of the acute period of cerebral ischemia.

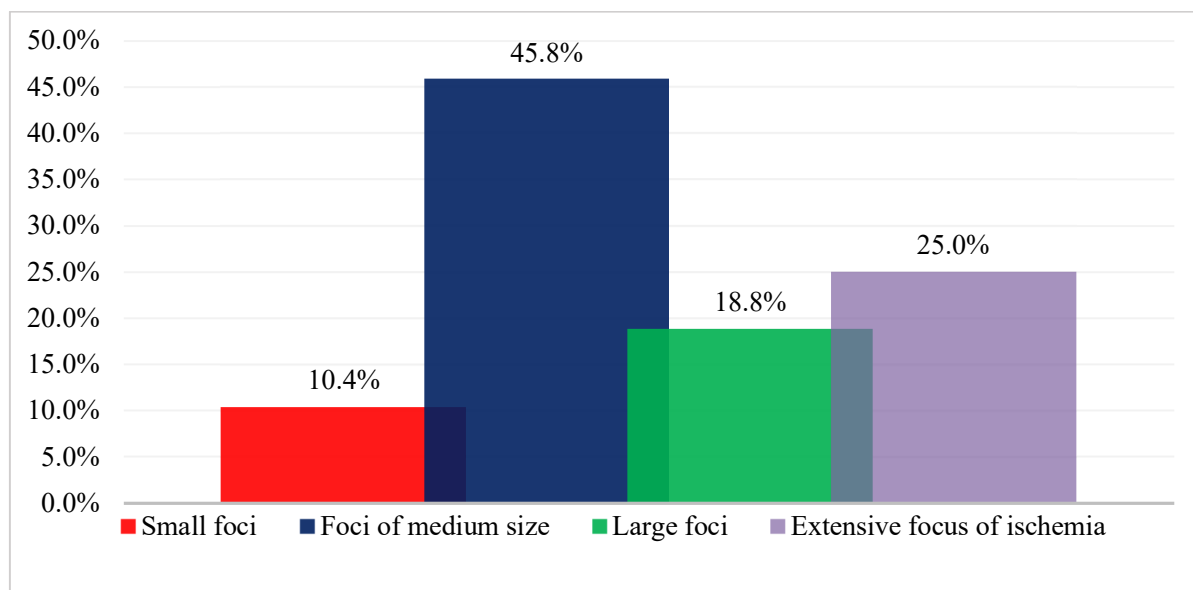


Fig. 1. Distribution of patients with ischemic stroke by the size of the foci of infarction

When assessing the correlation between the size of the focus of increased signal intensity on DWI-MRI and the area of the foci on perfusion maps (Fig. 2, 3 and 4), i.e., when studying the relationship of the initial structural changes with functional ones, the highest closeness of the correlation was noted for the CBV parameter ($r=0.752$, $p<0.01$).

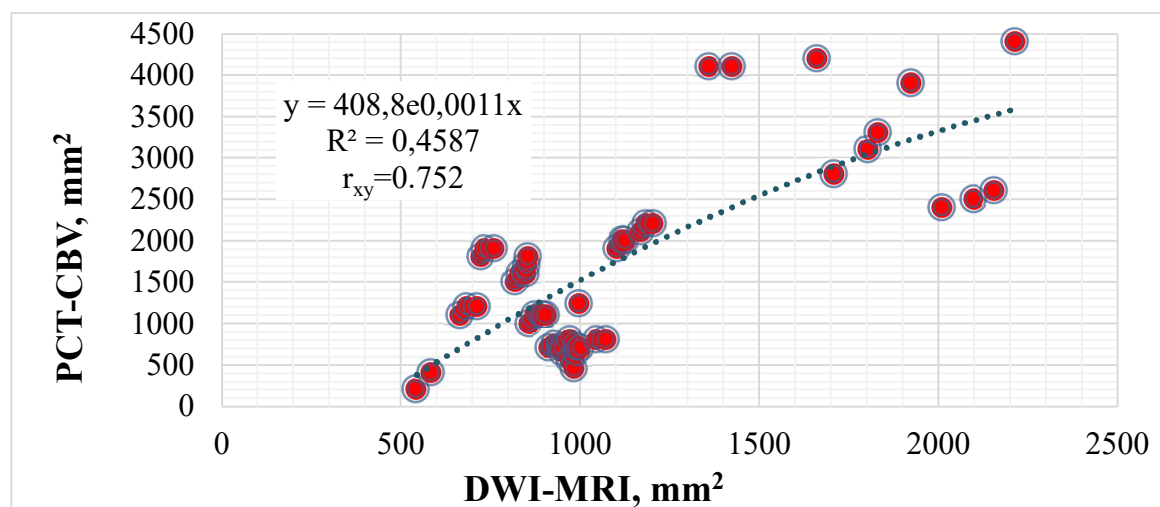


Fig. 2. Diagram of linear correlation between the size of ischemic foci on DWI-MRI and the area of foci on the CBV perfusion map

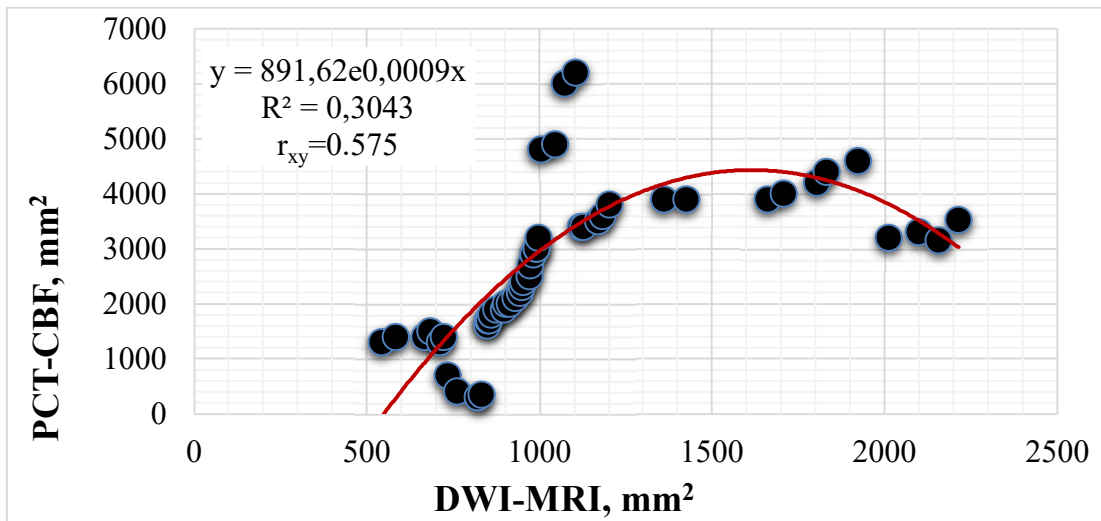


Fig. 3. Diagram of linear correlation between the size of ischemia foci on DWI-MRI and the area of foci on the CBF perfusion map

Also, a positive and noticeable closeness of the correlation with the size of the zone of altered diffusion was noted for both CBF ($r=0.575$, $p<0.05$) and MTT perfusion cards ($r=0.671$, $p<0.05$).

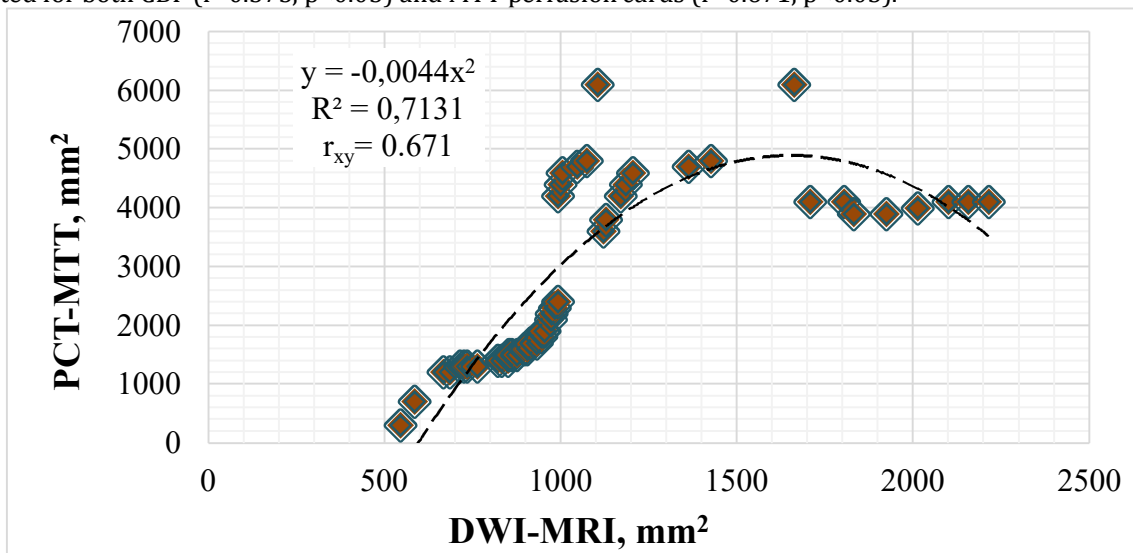


Fig. 4. Diagram of linear correlation between the size of ischemic foci on DWI-MRI and the area of foci on the MTT perfusion map

The analysis of the data of the initial examination of patients allowed us to identify patients with a mismatch of the size of the ischemic focus detected on perfusion maps CBV, CBF and MTT, with the areas of the ischemic focus (structural changes) on DWI-MRI. Also, 70.8% (34 out of 48) of cases with reversible perfusion changes on CBF and MTT cards, and without signal changes on DWI-MRI, i.e. patients with penumbra zone, were identified.

Further analysis of the distinctive characteristics of the results of radiation diagnostics of patients with ischemic stroke with and without the penumbra zone allowed us to identify some features. Thus, the areas of ischemic foci differed between PCT maps and DWI-MRI data. At the same time, there were more cases with altered CBF, CBV and MTT zones and areas of diffusion change on DWI-MRI among patients with penumbra ($p<0.001$). The clinical characteristics of patients with and without penumbra had no statistically significant difference, both at the initial examination and on the 12th day of the disease.

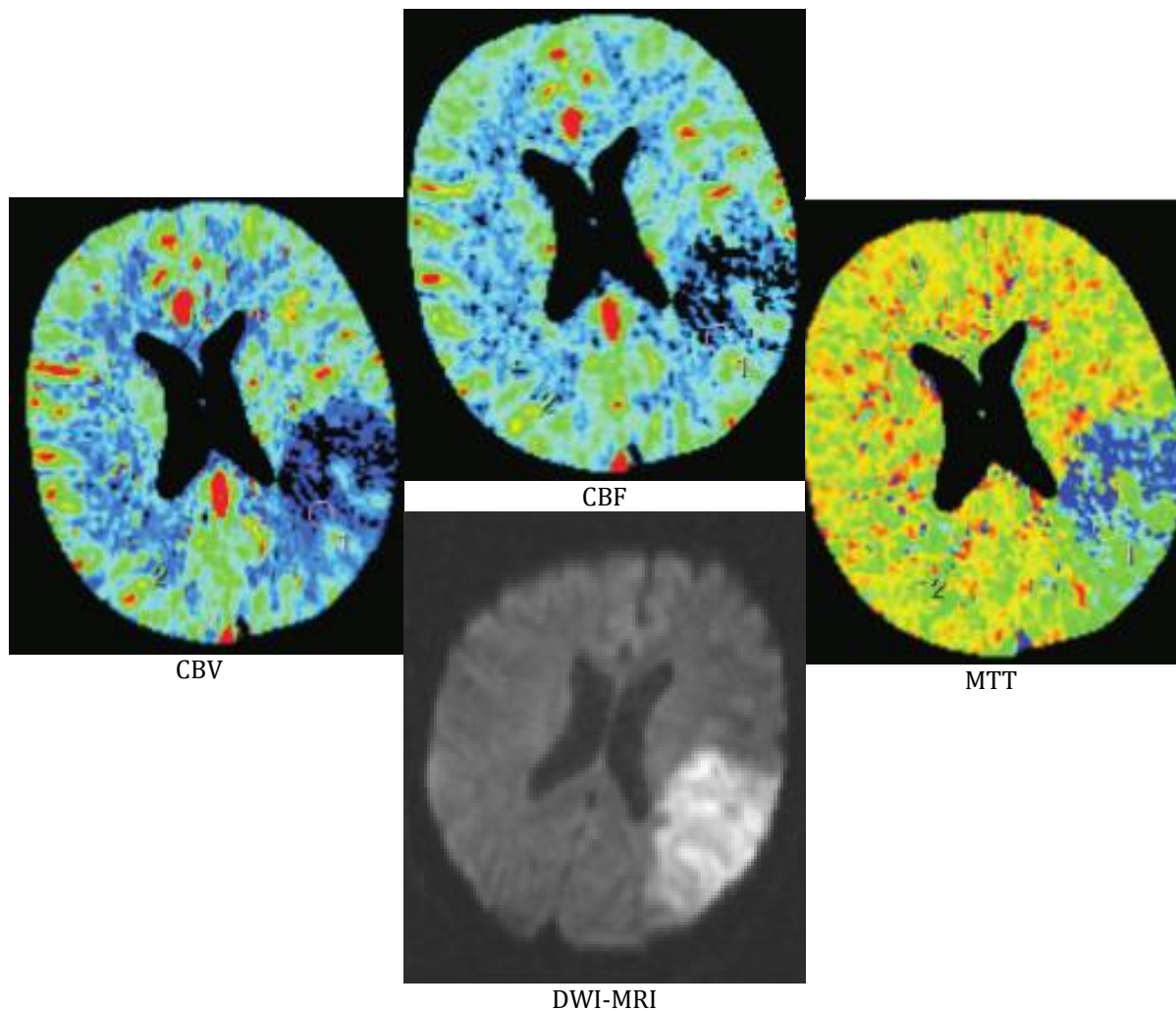
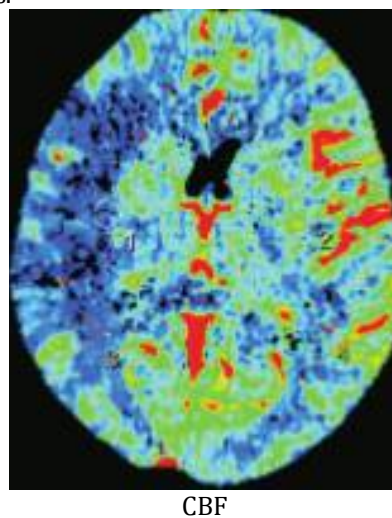


Fig. 5. Absence of zones of discrepancy between the size of the ischemic focus on DWI-MRI with the areas of perfusion cards CBV, CBF and MTT

Figure 5 shows MRI images and perfusion cards of PCT performed 9 hours after the start of the stroke clinic in patient A., 64 years old. It can be seen that the zone of the disturbed MR signal in the parietal and temporal regions of the left hemisphere of the brain visually coincides with the zone of perfusion disorders in all three CBV, CBF and MTT maps.



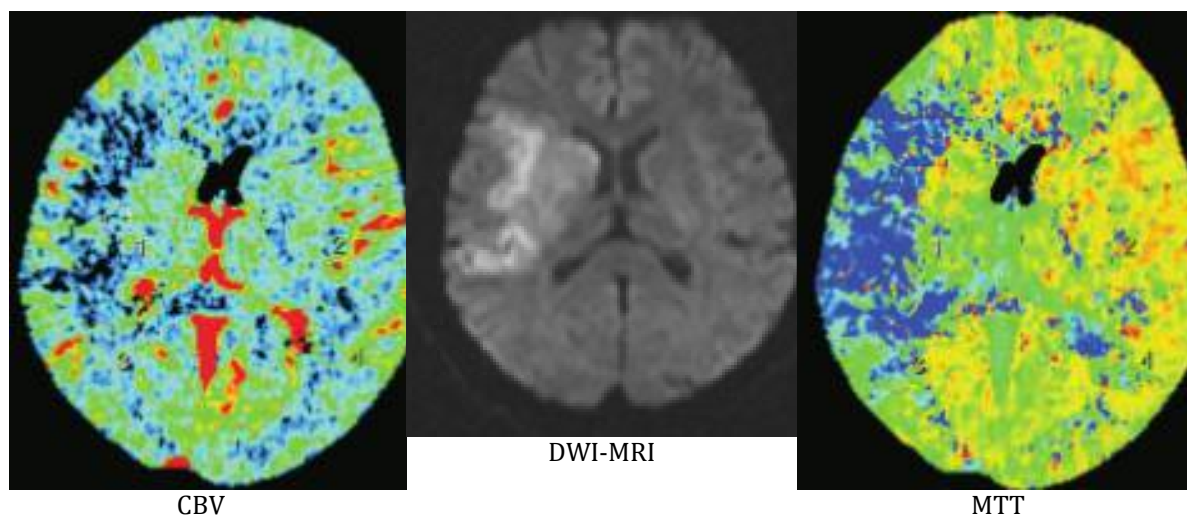


Fig. 6. Presence of areas of mismatch of the size of the focus on DWI-MRI with the areas of perfusion cards CBV, CBF and MTT

Figure 6 shows images of DWI-MRI and perfusion cards of PCT performed 7.5 hours after the start of the stroke clinic in patient B., 62 years old. It can be seen that the zone of the disturbed MR signal in the zone of the temporal region, subcortical structures and the upper frontal gyrus of the right hemisphere of the brain visually coincides with the zone of perfusion reduction on the CBV map. CBF and MTT. At the same time, we can immediately see how the areas of CBF reduction and increased MTT, where the frontal, temporal lobes, subcortical structures and partially occipital lobe of the right hemisphere of the brain are also covered, exceed the area of the focus on DWI-MRI.

Patients with penumbra on the PCT maps of the CBF decrease and MTT increase zones in their area exceeded with a statistical difference ($p < 0.01$) the zones of altered diffusion, and the CBV decrease maps do not have a significant difference in the area of the ischemic focus with the zones of impaired diffusion detected on DWI-MRI.

DISCUSSION

Unlike MRI, PCT visualizes a brain infarction indirectly based on perfusion changes. Therefore, small subcortical infarcts are more difficult to detect, and CTP is more prone to errors [9, 10]. Validation of PCT parameters and threshold values for the identification of the ischemic nucleus is based on the final volume of infarction on control MRI in patients with complete reperfusion. The variability of the optimal parameter or perfusion threshold is explained by differences in image acquisition (mainly brain volume coverage, image acquisition speed and scan duration), reference visualization and data processing methods (among others, placement of the input arterial function, deconvolution method and delay and variance correction) [11, 12].

A decrease in CBF compared to normal brain tissue (rCBF) most consistently and accurately identifies the ischemic nucleus. Since only a few studies have used MRI to check the thresholds of the ischemic nucleus, and since an increase in infarction may occur between the receipt of PCT data and reperfusion, confirmed CBF thresholds may overestimate the ischemic nucleus if perfusion imaging is obtained very early after the onset of symptoms [13-15]. Similarly, the ischemic nucleus may be overestimated if rapid reperfusion is achieved [13].

Lacunar or small subcortical infarcts are usually not detected using PCT thresholds, but visual examination, in particular, MTT and time-to-peak (TTP) maps have high specificity, but moderate sensitivity for detecting these infarcts [9, 16, 17].

Within a few minutes after the onset of a stroke, cytotoxic edema develops in the infarct tissue, characterized by restriction of the movement of water molecules. This is visualized as a decrease in the apparent diffusion coefficient and hyperintensity on DWI-MRI [18]. The threshold of the apparent diffusion coefficient is a sufficiently reliable parameter for determining the nucleus of ischemia [19]. Reversibility of acute lesions on DWI-MRI is observed on average in 24% of cases and is associated with a shorter duration of ischemia and reperfusion [20]. Significant and permanent reversal of DWI in patients with acute stroke undergoing reperfusion treatment, however, is rare and probably has no clinical significance [21].

Penumbra is obtained by subtracting the ischemic nucleus from perfusion deficiency (the total volume of brain tissue with critical hypoperfusion). PCT and MRI can successfully distinguish perfusion deficiency from normal brain tissue or benign oligemia. Optimal perfusion parameters are mainly confirmed by comparison with the final MRI infarction in the absence of reperfusion. The differences in the optimal parameter and threshold are partially explained by the deconvolution method and other postprocessing algorithms. Although deconvolution perfusion parameters are commonly used, maps without deconvolution can be just as accurate [22, 23].

A feature of the data obtained in patients without a penumbra zone is the lack of differences between the areas of zones with reduced CBF, CBV and increased MTT and the area of altered diffusion on DWI-MRI. In particular, our study was also aimed at obtaining data on the relationship between the results of PCT and MRI in patients with acute cerebral ischemia. DWI-MRI revealed areas with increased signaling intensity with an area of $1125.7 \pm 431.8 \text{ mm}^2$ (from 544.0 to 2214.0 mm^2) in all patients. Cases of medium-sized heart attacks prevailed among patients (45.8%; 22 out of 48). A high correlation was revealed between the size of the focus of increased signal intensity on DWI-MRI and the area of foci on the CBV perfusion map ($r=0.752$, $p<0.01$), and a noticeable closeness of correlation with the areas of ischemic foci on CBF maps ($r=0.575$, $p<0.05$) and MTT ($r=0.671$, $p<0.05$). Patients with the presence of a penumbra zone were distinguished by a higher frequency of cases with areas of diffusion change on DWI-MRI ($p<0.001$). Moreover, in cases of penumbra, CBF reduction and MTT increase maps had areas of ischemia zones exceeding ($p<0.01$) zones of altered diffusion, and CBV reduction maps corresponded to zones of impaired diffusion on DWI-MRI. The absence of penumbra suggested that there were no differences between the areas of the ischemic zone with impaired CBF, CBV, MTT and the area of diffusion changes on DWI-MRI. Thus, the combination of PCT and CT provides important diagnostic information regarding the degree of infarction and perfusion deficiency. The characteristics of lesions on PCT-CBV maps do not differ from lesions on DWI-MRI, as well as lesions on the original CT-angiography images do not differ from lesions on DWI-MRI. In cases where DWI-MRI is not available or a combination of CT without contrast enhancement cannot be performed, PCT and CT angiography provides comprehensive information within less than 20 minutes and facilitates therapeutic decision-making.

Despite the fact that there were no significant differences (in a number of clinical and imaging signs) between patients with restored blood flow and patients with persistent perfusion deficiency, it is necessary to note the tendency to large areas of reduced CBF and increased MTT in the group of patients with persistent areas of perfusion impairment. In this connection, the disappearance of the foci of altered perfusion reflected the regression of neurological deficit.

CONCLUSION

In patients with ischemic stroke, there is a high correlation between the parameters of cerebral perfusion measured on PCT and MRI signs. Visualization of ischemic stroke using modern methods of PCT and MRI with quantitative assessment of blood flow through the parenchyma of the brain increases the accuracy of diagnosis, allows you to determine the goals of treatment and can provide prognostic information about the functional outcome of the patient.

REFERENCES

1. Feigin VL, Nguyen G, Cercy K, et al. (2018). Global, regional, and country-specific lifetime risks of stroke, 1990 and 2016. *N Engl J Med.* 379: 2429-2437. DOI: 10.1056/NEJMoa1804492
2. Sacco RL, Kasner SE, Broderick JP et al. (2013). An updated definition of stroke for the 21st century: a statement for healthcare professionals from the American Heart Association/American Stroke Association. ;44(7):2064-89. doi: 10.1161/STR.0b013e318296aeca.
3. GBD 2016 Stroke Collaborators. Global, regional, and national burden of stroke, 1990–2016: a systematic analysis for the Global Burden of Disease Study 2016. *Lancet Neurol.* 2019; 18: 439-458. doi: 10.1016/S1474-4422(19)30034-1.
4. Zhang XH, Liang HM. (2019); Systematic review with network meta-analysis: Diagnostic values of ultrasonography, computed tomography, and magnetic resonance imaging in patients with ischemic stroke. *Medicine (Baltimore).* 98(30):e16360. doi: 10.1097/MD.0000000000016360.
5. Jelle Demeestere, (2020). Anke Wouters, Soren Christensen, Robin Lemmens and Maarten G. Lansberg. Review of Perfusion Imaging in Acute Ischemic Stroke. *Stroke.* 51(3):1017-1024. <https://doi.org/10.1161/STROKEAHA.119.028337>
6. Gonzalez RG, Lev MH, Goldmacher GV, et al. (2012). Improved outcome prediction using CTA in addition to standard ischemic stroke assessment: results from the STOP Stroke study. *PLoS One* 7:e30352.
7. Lovblad KO, Baird AE. (2010). Computed tomography in acute ischemic stroke. *Neuroradiology.* Mar;52(3):175-87. doi: 10.1007/s00234-009-0633-5.

8. Drake M, Frid P, Hansen BM, Wu O, Giese A-K, Schirmer MD, Donahue K, Cloonan L, Irie RE, Bouts MJRJ, et al. (2020). Diffusion-Weighted Imaging, MR Angiography, and Baseline Data in a Systematic Multicenter Analysis of 3,301 MRI Scans of Ischemic Stroke Patients—Neuroradiological Review Within the MRI-GENIE Study. *Front. Neurol., Sec. Stroke*. 11. <https://doi.org/10.3389/fneur.2020.00577>.
9. Cao W, Yassi N, Sharma G, Yan B, Desmond PM, Davis SM, et al. (2016). Diagnosing acute lacunar infarction using CT perfusion. *J Clin Neurosci*. 29:70–72. doi:10.1016/j.jocn.2016.01.001.
10. Wintermark M, Flanders AE, Velthuis B, Meuli R, van Leeuwen M, Goldsher D, et al. (2006). Perfusion-CT assessment of infarct core and penumbra: receiver operating characteristic curve analysis in 130 patients suspected of acute hemispheric stroke. *Stroke*. 37:979–985. doi: 10.1161/01.STR.0000209238.61459.39.
11. Zussman B, Jabbour P, Talekar K, Gorniak R, Flanders AE. (2011). Sources of variability in computed tomography perfusion: implications for acute stroke management. *Neurosurg Focus*. 30:E8. doi: 10.3171/2011.3.FOCUS1136.
12. Bivard A, Levi C, Spratt N, Parsons M. (2013). Perfusion CT in acute stroke: a comprehensive analysis of infarct and penumbra. *Radiology*. 267:543–550. doi: 10.1148/radiol.12120971
13. d'Esteire CD, Boesen ME, Ahn SH, Pordeli P, Najm M, Minhas P, et al. (2015). Time-dependent computed tomographic perfusion thresholds for patients with acute ischemic stroke. *Stroke*. 46:3390–3397. doi: 10.1161/STROKEAHA.115.009250.
14. Mokin M, Levy EI, Saver JL, Siddiqui AH, Goyal M, Bonafé A, et al; (2017). SWIFT PRIME Investigators. Predictive value of RAPID assessed perfusion thresholds on final infarct volume in SWIFT PRIME (Solitaire With the Intention for Thrombectomy as Primary Endovascular Treatment). *Stroke*. 48:932–938. doi: 10.1161/STROKEAHA.116.015472.
15. Hoving JW, Marquering HA, Majoie CBLM, Yassi N, Sharma G, Liebeskind DS, et al. (2018). Volumetric and spatial accuracy of computed tomography perfusion estimated ischemic core volume in patients with acute ischemic stroke. *Stroke*. 49:2368–2375. doi: 10.1161/STROKEAHA.118.020846.
16. Benson JC, Payabvash S, Mortazavi S, Zhang L, Salazar P, Hoffman B, et al. (2016). CT perfusion in acute lacunar stroke: detection capabilities based on infarct location. *AJNR Am J Neuroradiol*; 37:2239–2244. doi: 10.3174/ajnr.A4904.
17. Rudilosso S, Urra X, San Román L, Laredo C, López-Rueda A, Amaro S, et al. (2015). Perfusion deficits and mismatch in patients with acute lacunar infarcts studied with whole-brain CT perfusion. *AJNR Am J Neuroradiol*. 36:1407–1412. doi: 10.3174/ajnr.A4303.
18. Hjort N, Christensen S, Sølling C, Ashkanian M, Wu O, Røhl L, et al. (2005). Ischemic injury detected by diffusion imaging 11 minutes after stroke. *Ann Neurol*. 58:462–465. doi: 10.1002/ana.20595.
19. Purushotham A, Campbell BC, Straka M, Mlynash M, Olivot JM, Bammer R, et al. (2015). Apparent diffusion coefficient threshold for delineation of ischemic core. *Int J Stroke*. 10:348–353. doi: 10.1111/ijvs.12068.
20. Kranz PG, Eastwood JD. (2009). Does diffusion-weighted imaging represent the ischemic core? An evidence-based systematic review. *AJNR Am J Neuroradiol*. 30:1206–1212. doi: 10.3174/ajnr.A1547.
21. Campbell BC, Purushotham A, Christensen S, Desmond PM, Nagakane Y, Parsons MW, et al; (2012). EPITHET-DEFUSE Investigators. The infarct core is well represented by the acute diffusion lesion: sustained reversal is infrequent. *J Cereb Blood Flow Metab*. 32:50–56. doi: 10.1038/jcbfm.2011.102.
22. Wouters A, Christensen S, Straka M, Mlynash M, Liggins J, Bammer R, et al. (2017). A comparison of relative time to peak and tmax for mismatch-based patient selection. *Front Neurol*. 8:539. doi: 10.3389/fneur.2017.00539
23. Christensen S, Mouridsen K, Wu O, Hjort N, Karstoft H, Thomalla G, et al. (2009). Comparison of 10 perfusion MRI parameters in 97 sub-6-hour stroke patients using voxel-based receiver operating characteristics analysis. *Stroke*. 40:2055–2061. doi: 10.1161/STROKEAHA.108.546069.

CITATION OF THIS ARTICLE

Djuraeva N.M., Amirkhamzaev A.T. Magnetic Resonance Imaging and Perfusion Computed Tomography in The Diagnosis of Ischemic Brain Damage. *Bull. Env. Pharmacol. Life Sci.*, Vol 12[10] September 2023: 13-20.