



ORIGINAL ARTICLE

Morphological Evaluation of Pterygoid Hamulus through Mprcone- Beam Computed Tomography Images

Mehri Khoubivand¹, Roshanak Ghaffari^{2*}, Maryam Anjomshoa³

1-Resident of Oral and Maxillofacial Radiology, Dental School, Islamic Azad University Isfahan (khorasgan)Branch, Isfahan, Iran

2-Assistant Professor, Department of Oral and Maxillofacial Radiology in Dental school. Islamic Azad University Isfahan(khorasgan)Branch, Isfahan, Iran

3-Assistant Professor, Department of Anatomy, Dental School, Islamic Azad University Isfahan (khorasgan) Branch, Isfahan, Iran

Email: Roshanakghaffari@yahoo.com

ABSTARCT

The aim of this study is to accumulate sufficient morphological data about the Pterygoid Hamulus (PH) using multiplanar reconstructed (MPR) cone beam computed tomography (CBCT) images to enable an experimental interpretation to be provided. The CBCT scans of 136 (82 men and 54 women) patients ranging in age from 20-55 and older than 55 years old were analyzed. The Width, length and angle were measured. In addition, the inclinations of PHs also evaluated in coronal and sagittal planes of the MPR images. Independent t-test, Pearson correlation and paired t-test were performed for statistical analyzed. ($p < 0.05$) The mean PH measurements of left, right and total sides were 7.55 (SD 2.17), (SD 2.08) And 7.48 (SD 2.06) – mm lengths, 1.48 (SD 0.28), 1.43 (0.32) and 1.46 (SD 0.25) –mm widths, and the inclinations were 58.98° (SD 8.79°), 58.8° (SD 8.99°) and 58.89° (SD 8.25°) in the sagittal plane and 61.27° (SD 8.71°), 60.07° (SD 8.84°) and 60.67° (SD 8.23°) in the coronal plane, respectively. The paired t-test showed no statistically difference left and right sides measurements except for the inclination of PH in the left sides of coronal plane. ($p = 0.02$). All PHs were inclined toward the lateral and posterior in the coronal and sagittal planes respectively. Assessment of PH morphology in the CBCT images, help to trace and manage of vague and undiagnosed symptoms related to PH morphology and elongation in the oral cavity but considering bilaterally elongated PH as etiologic factor for PH syndrome should be cautiously.

Key words: .Cone-Beam Computed Tomography [E01.370.350.700.810.810.490], Pain [C10.597.617], palate [A14.521.658], Sphenoid Bone [A02.835.232.781.802]

Received 12.09.2014

Revised 23.11.2014

Accepted 21.12.2014

INTRODUCTION

The pterygoid hamulus (PH), a structure on the under surface of the skull base which has so far hardly been described, is in peculiar situation biomechanically [1].

The position, length, and inclination of the PH are of great importance for the function of several muscles: tensor veli palatini, palatopharyngeus, and upper part of the upper pharyngeal constrictor, pars pterygopharyngea. These muscles contribute to the separation of the oral from the nasal cavity during sucking and swallowing. This separation is accomplished by the elevation of the soft palate because of the constriction of levator veli palatini and tubar part of muscle tensor veli palatini, contraction of the pars pterygopharyngea of the upper pharyngeal constrictor, and stretching of the palatal aponeurosis by the tensor veli palatine. The position, length of PHs are important for these functions, especially in relation to width of the hard palate [2].

According to several studies conducted on the position and morphology of PH in different populations, the length of the PH was found to be within the range of 4.9 to 7.2 mm [1-6]. Putz and Kroyer¹ also reported the sagittal and transverse diameter of PH as 1.4 mm and 2.3 mm, respectively, whereas Sasaki et al [6] also reported an elongated PH of 13 mm. Orhan et al⁵ found the mean PH measurements of left

and right sides 1.72 and 1.87mm width, and the lengths were 5.48 and 5.40 mm, respectively. Moreover, all studies reported that the positions of PHs are inclined laterally in the coronal plane [1,2,5].

Pain in the region of the soft palate and pharynx is a diagnostic dilemma. There are a number of publications, limited to case reports that have made reference to etiological causes of this clinical problem [6]. Any of the following factors may be responsible: bursitis or an osteophyte in the tensor veli palatini, elongation of the PH, consistent repetition of minimal trauma to the overlying soft tissue and pH, hyper awareness of the pH, muscular discoordination, or fracture of the PH after extensive and repeated manipulation [4]. Hjørting- Hansen and Lous [7] were the first to coin the term pterygoid hamulus syndrome which described pain in the palate and pharyngeal area as a result of an abnormal growth of a pterygoid hamulus.

Common symptoms include sharp or burning pain in the palatal and pharyngeal region that may remain localized or refer to the ipsilateral ear or temporomandibular joint. This may occur spontaneously or elicited by touch or eating and drinking [8]. Thus, knowledge about the morphology of these structures is helpful for the interpretation of imaging and provides valuable information in the differential diagnosis of untraceable pains in the oral cavity and pharynx.

The detection of this area can be achieved by radiography (cephalometric radiography, submentovertex, Waters view, and so forth); however, identification of these structures by conventional radiography is exceedingly difficult because of superimposition and distortion. Three-dimensional computed tomography (CT) by avoiding of this problems permits evaluation of the craniofacial structures from unobstructed perspectives and with less distortion than plane film views [9]. Unfortunately, this technique suffers from relatively high cost and high radiation dose [10]. In the past decade, CBCT devices have been developed for head and neck imaging. The characteristics of these dedicated maxillofacial devices, including reduced cost and dose, are well suited for imaging the craniofacial area [11]. Despite various studies that were conducted on shape, length, and position of the PH, the anatomical relations of pH and the surrounding structures are rarely investigated [1-4]. This study took advantage of MPRCBCT images for evaluating of PH.

MATERIAL AND METHODS

In this descriptive –analytic study left and right sides of the CBCT scans of 136(82 men and 54 women) patients ranging in age from 20-55 and elderly (55<) were analysed. The study's protocol was carried out according to the principles described in the Declaration of Helsinki, including all amendments and revisions. CBCT images were recommended for various purposes such as paranasal sinus examinations, preimplant and orthodontic purposes. Iranian patients older than 20 years old were included in the study with no preference in regard to gender. In addition, only high-quality CBCT images were evaluated. CBCT scans were captured by SCNORA 3D-SOREDEX-TUUSULA-FINLAND CBCT using flat panel CMOS providing high resolution images with 0.25 mm voxel size. Mesuring on MPR images were performed using ON DEMAND 3D version 1 software. Measurements accurate were about 0.01 mm. The slice thickness was 0.2 mm.

After standard positioning and obtaining image, if the head position was not desirable on the display monitor, it was adjusted by using Axis Relics software. All measurements were obtained by Putz and Kroyer's proposed method. Following same way in measuring help to researchers to compare findings of different studies easily. Figure (1) shows Putz and Kroyer's method schematically [1].

To standardize the measurements, reference points were chosen. The length measurements were taken from the junction of medial pterygoid plate and PH through the tip. First a line was drawn from the junction of medial pterygoid plate and pH parallel to the horizontal plane. Following the identification of the midpoint of this line, the length was measured starting from this point to the tip of the pH (Fig 2, a). The width of the pH was measured as the distance between the most prominence points of the PH in the coronal plane (Fig 2, b). In addition, the inclinations of PHs were evaluated in sagittal and coronal planes of the MPR images. The average degrees of inclinations in the sagittal and coronal planes were also calculated by means of the software (Fig 3). The inclination of pH in the sagittal plane and coronal plane were classified visually to anterior or posterior and medial or lateral respective. All measurements were done by a resident of radiology under supervision of an oral and maxillofacial radiologist and an anatomist. These measurements were noted for analyses. Some of measurements were done again after 2 weeks. Patients with pH length more than 10mm were asked about painful and burning sensations in the soft palate and pharynx. The posterior part of tuberosity was examined by palpati onto assess swelling and pain.

The data files entered into SPSS software program. Statistical analyses were carried out using independent t-test, Pearson correlation and Paired t-test for showing relation between the quantitative

measures with sex, age and two sides. Pearson correlation between two times measurement show $r=0.94$. ($p<0.001$)

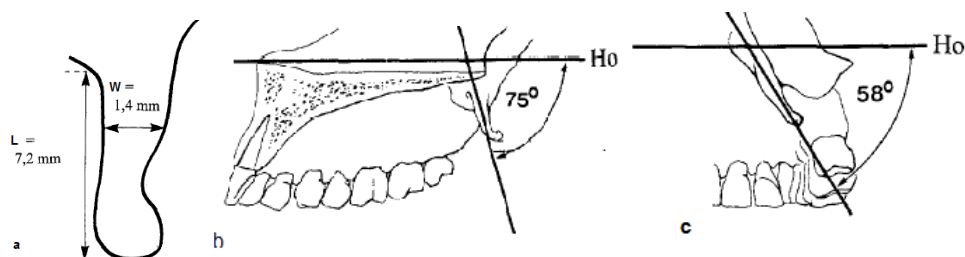


Fig.1.a,b,c, Linear dimensions of PH, L(length) and W(width) a, Inclination of PH in sagittal plane b, Inclination of PH in coronal plane c.

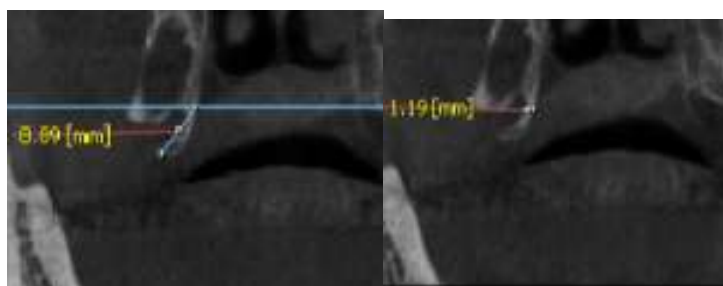


Fig. 2.a,b, MPR CBCT images show measuring a, length and b, width of PH in the coronal plane

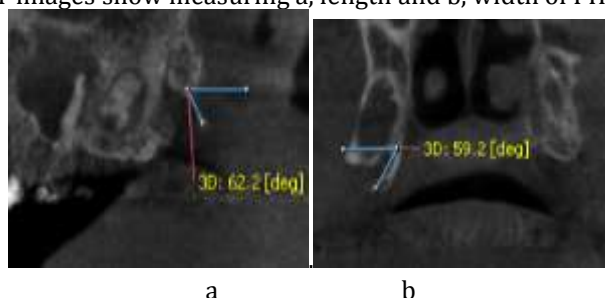


Fig.3.a,b, MPR CBCT images show angulation measurement of PH a, in the sagittal plane b, in the coronal plane.

RESULTS

A total of 272 left and right sides of MPR CBCT images of 136 subjects (82 men and 44 women) ranging in 20-82 years (mean: 50.2 ± 13.1) were investigated. The findings are presented in Table I. The mean measurements of PH in the left, right and total sides were 7.55 ± 2.17 , 7.42 ± 2.08 and 7.48 ± 2.06 – mm lengths, 1.48

± 0.28 , 1.43 ± 0.32 and 1.46 ± 0.25 – mm width, respectively. The average inclination of left, right and total sides were $58.98^\circ \pm 8.79^\circ$, $58.8^\circ \pm 8.99^\circ$ and $58.89^\circ \pm 8.25^\circ$ in the sagittal plane and $61.27^\circ \pm 8.71^\circ$, $60.07^\circ \pm 8.84^\circ$ and $60.67^\circ \pm 8.23^\circ$ in the coronal plane, respectively.

Paired t – test revealed no statistically significant differences between left and right measurements except for the mean of inclination in coronal plane on the left side that were more than right side ($p=0.02$). Independent t-test showed no statistically significant differences in the measurements obtained from female and male, for inclination of PH in the left and right sides and width, in the coronal plane. But the rest of measurements in the male were more than female. In addition, the Independent t-test showed no statistically significant differences between 20-55 and older than 55 years except for the width of PHs in the coronal plane in 20-55 years old were less than the old. In the coronal and sagittal plane, it was found that all PHs were inclined lateral and posterior sides respectively.

Pearson correlation revealed some relationship between the measurements that presented in Table II. It also disclosed that there is statistically significant relationship between the length of PH with the inclination of PH in sagittal plane, coronal plane and width of PHs in coronal plane ($p<0.001$, $p<0.031$ and $p=0.019$, respectively)

Table I. Mean measurements with standard deviations(SD) of Hamulus Pterygoid(PH), width(W),length(L)and inclination(I) on sagittal(S) and coronal(C) planes in femal and male ranging in age 20-55 and 55<

	Left PH measurements(Mean± SD)				Right Measurements (Mean± SD)			
	IS	IC	LC	WC	IS	IC	LC	WC
Female	56.16± 8.61	60.22± 8.02	7.06±1.85	1.47±0.25	55.33± 7.85	59.34± 8.45	6.86± 1.71	1.39± 0.32
male	60.82± 8.46	61.96± 9.11	7.87±2.31	1.54±0.28	61.09± 9.0	60.55±9.11	7.79± 2.23	1.46± 0.31
Total	58.97 ± 8.79	61.27± 8.71	7.55±2.17	1.48± 0.28	58.80± 8.99	60.07±8.84	7.42±2.08	1.43± 0.32
20-55	57.97± 8.68	60.49± 8.49	7.44± 2.14	1.47±0.24	59.27± 9.09	59.42± 8.57	7.27± 2.11	1.37± 0.29
<55	60.45± 8.83	62.41± 8.97	7.71± 2.21	1.50± 0.32	59.59± 8.86	61.02±9.22	7.64± 2.04	1.52± 0.34
Total	58.97± 8.79	61.27± 8.71	7.55± 2.17	1.48± 0.28	58.80± 8.99	60.07± 8.84	7.42± 2.08	1.43± 0.32

Table II: The Pearson correlation(r) and P-value with Hamulus Pterygoid (PH) parameters

		Width of PH in coronal plane	Length of PH in coronal plane	Inclination of PH in coronal plane	inclination of PH in sagittal plane
Inclination of PH in sagittal plane	r	0.297	0.407	-0.131	1
	P-value	0.001	0.000	0.128	-
Inclination of PH in coronal plane	r	0.074	0.186	1	-0.131
	P-value	0.390	0.031	-	0.128
Lengthof PH in coronal plane	r	0.200	1	0.186	0.407

DISCUSSION

The Pterygoid Hamulus (PH) is a hook shaped bone projecting downward dorsolaterally from the medial pterygoid plate [4]. Although the PH is, because of its bizarre shape, a striking feature of the skull base, it is still an unexplored region on the anatomical map. However, its close topographic relationship to the distal end of the upper dental arch renders it of interests to all disciplines that are involved with this region [1].

Putz and kroyer (1) investigated on PH areas for attachment of muscle tensor veli palatine, muscleconstrictor pharynges, pars pterygop Haryngis and buccopHaryngea, RapHe pterygomandibularis, musclebuccinator and muscle pterygoideus medialis [1].

Muscles tensorveli palatini originates from the spina ossissphenoidalis, medial to the oval foramen andforamen spinae, and from the fossa scaphoidea and lateral wall of the pharyngeal tube. Running downwards, it uses the sulcus hamuli pterygoidei asa hypomochlion to change the direction and continue as a flat tendon to form most of the palatal aponeurosis. A synovial bursa within the sulcus hamuli is responsible for the gliding of the tendon. The contraction of the muscle produces the tension and elevation of the soft palate. The part of the muscle originating from the tuber wall is fixed to the hamulus and functions as muscle dilatators of the pharyngeal tube [2].

The medial lamina of the pterygoid process, the hamulus, the buccopharyngeal raphe and mandibular insert one of the raphe displayed a solid framework for the insertion of the muscles constricting and lifting the pharyngeal tube. Only when the hamulus reaches a certain length and it is firmly fixed to the crista buccinatoria of the mandible by means of the raphe buccopharyngeal, the muscles cephalopharyngeus can fulfil its task-full separation, together with muscles tensor veli palatine of the oral from the nasal cavity. The inclination of the hamuli and the difference between the width of the hard palate and the distance between the tips of hamuli is responsible for better tention of the palatal aponeurosis. If the hamulus remains short as in the newborns, the muscles cephalopharyngeus does not have a firm support and its contraction will lead to uncontrolled narrowing of the upper pharynx and thus cause problems, like snoring or sleep apnea [2]. Besides, the elongated PH can also be the reason for pain and discomfort in the soft palate and pharynx [6]. Such cases have been previously reported. Gores [2] was the first to report the presence of pain caused by a long PH.

Previously, several etiologic factors stated bursitis of TV or an osteophyte [4, 14-16] elongation of PH [4-6] or consistent minimal trauma to the overlying structure¹⁷thtrauma from swallowing a large bolus of

food or from an overextended denture, anesthesia intubations, trauma during tooth brushing, bulimic patients, and “fellatio” in child abuse seem to be other causes of this syndrome.^{6,18} In Orhan⁵ reported case, third molar extraction was etiologic factor. The differential diagnosis should include tumors, cysts, infections, foreign bodies, elongated styloid syndrome, third molar eruption, TMJ diseases, muscular dysfunction and also elongated PH.^{4,6,18}

When the pterygoid hamulus be responsible for atypical pain. Common symptoms include sharp or burning pain in the palatal and pharyngeal region that may remain localized or refer to the ipsilateral ear or temporomandibular joint. This may occur spontaneously or elicited by touch or eating and drinking [8]. Firm swelling and erythema of the palatal mucosa over the hamulus are also common signs [6, 14, 18]. Shankland [19] suggests that diagnostic testing with local anesthesia may be valuable if a local cause has been identified.

Several studies describe the morphology of PH in different populations. Eyrich et al [4] found the mean length of the left hamulus to be 5 mm and the right to be 4.9 mm. Putz and Kroyer [1] reported the average length to be 7.2 mm and the sagittal and transverse diameter to be 1.4 mm and 2.3 mm, respectively. Sasaki et al [6] reported an elongated PH case of 13 mm. Also they found the mean length of PH to be 6.8 mm. Krmpotic´-Nemanic´ et al. [2] conducted an extensive study on PH. They investigated the PH among 3 age groups: children (0-9), adults (21-59), and elderly (60-100). They found that children had the shortest PH length, on average 3.6 mm. The length increased in adults (6.9 mm) and then decreased significantly again to 5.0 mm in the elderly group. They also found no statistical difference for gender and for left and right sides. Recently Orhan et al. [5] showed the mean length of PHs for left and right sides were 5.48 (SD 1.94) and 5.40 (SD 2.0) mm, respectively with no significant difference according to gender and location. They reported an elongated PH(10.9 mm) in a young female.

This study showed the mean length of PHs for left, right sides and in total were 7.55 (SD 2.17) , 7.42 (SD 2.08) mm and 7.48 (SD 2.06) , respectively with no significant difference according to age. Also we found that female had PH shorter length than male. We encountered several subject with PH length more than mean length defined in literatures such as 15.1 mm in a 52 years old male (figure 4), 14.28 mm in 50 years old male and 13.99 mm in 75 year old male patient and so forth. It was expected patients with elongated PH complain of some atypical symptoms that were mentioned above, but it was vice versa surprisingly. They didn't have any complain such as painful and burning sensations when examined their soft palate and pharynx but there were firm swelling relatively during palpation of PH region. With regarding to all the bilaterally elongated PH in our study were asymptomatic support the theory muscular dyscoordination and imbalance muscular function due to PH overgrowth caused by various factors after ended developmental age of H may cause symptoms. *In the review of case reported articles* we noticed PH syndrome occurred after developmental age. So the elaborated assessment of etiologic factors especially in bilaterally cases prevents misdiagnosis specially in the cases need to surgical interventions. In this research we encountered some patient with short PHs. Some of the patient had unilaterally short PH with history of third molar extraction so they didn't include in study.

There were no differences in the measurements obtained from the age groups. This is coincide with Putz and Kroyer's [1] study, which reported that the PH increases in length to the beginning of adulthood, and thereafter remains unchanged throughout life but not in line with Krmpotic´-Nemanic´ et al. [2] and Orhan et al [5] study that reported older patients had shorter PH length than they younger patients. There was only few study regarding the width and the inclination of the PH. Putz and Kroyer [1] measured width of PH as 1.4 mm and Orhan measured width of PH as 1.72 (SD 0.94) and 1.87 (SD 1.17) mm for left and right, respectively. We found total width of PH 1.46 (SD 0.25) that is in line with Putz and Kroyer's study. The inclination of PH in Putz and Kroyer's (1) study were 75° in the sagittal plane and 58° in the coronal plane that were also similar to our results (Table I). All hamuli in this study were inclined dorsolaterally similar to Putz and Kroyer's study.

Our findings on MPR CBCT images that obtained a group of Iranian population, from a length, width and inclination point of view were in line to Putz and Kroyer's [2] measurements on skulls performed by sliding gauge in Germany but it show relatively differences with Orhan et al.'s ⁵study that were performed in Turkey on 3D images of CBCT.

Elongation of the PH is a rare syndrome that shows various and complex symptoms in the palatal and pharyngeal region. Radiographs of the PH and pterygomaxillary region should be obtained for the findings of osteophytes or hamular fracture or for any other abnormality. The detection of this area can be achieved by radiography (cephalometric radiography, submentovertex, Waters view, conventional tomography). However, identification of these structures by conventional radiography is exceedingly difficult because of superimposition and distortion. CT can be performed in axial and coronal planes with 3D views for diagnosis and treatment of this region [20-22]. The 3D CT avoids the superimposition and problems owing to magnification and offers visualization of the craniofacial structures with more

precision than the 2D conventional methods [23-25]. Despite these advantages, the effective dose of CT is much higher than the conventional radiographs and also expensive procedures and scanners are not easily accessible [24, 26, 27]. In the past decade, CBCT was proposed for maxillocraniofacial imaging [28-31]. Newer CBCT techniques provide high-resolution images of high diagnostic quality with significantly reduced acquisition time and radiation burden. Reformatted from CBCT imaging data have been shown to have measurement accuracy equivalent to MDCT imaging data [32].




Figure 4 a.b. MPR CBCT image of same patient with bilaterally elongated PH

CONCLUSIONS

The Pterygoid Hamulus can be responsible for atypical pain in the oral cavity and pharynx, as well as its close topographical relationship to the distal end of the upper dental arch renders it of interest to all disciplines that are involved with this region. Assessment of PH morphology in the CBCT images help to trace and managements of ambiguous and conflicting symptoms related to PH morphology and elongation in the oral cavity. Considering bilaterally elongated PH as etiologic factor for PH syndrome should be cautiously.

REFERENCES

1. Putz R, Kroyer A. (1999). Functional morphology in the pterygoid hamulus. *Ann Anat*;181:85-8.
2. Krmpotić-Nemanic J, Vinter I, Marusic A. (2006). Relations of the Pterygoid Hamulus and hard palate in children and adults: anatomical implications for the function of the soft palate. *Ann Anat*;188:69-74.
3. Abe M, Murakami G, Noguchi M, Kitamura S, Shimada K, Kohama GI, et al. (2004). Variations in the tensor veli palatini muscle with special reference to its origin and insertion. *CleftPalateCraniofac J* 2004;41:474-84
4. Eyrich GK, Locher MC, Warnke T, Sailer HF. (1997). The pterygoidhamulus as a pain-inducing factor. A report of a case and aradiographic study. *Int J Oral Maxillofac Surg*;26:275-77
5. Orhan K, Sakul BV, Oz U, Bilecenoglu B. (2011). Evaluation of the Pterygoid Hamulus morphology using cone beam computed tomography. *Journal of Oral Surg Oral Med, Pathol, Oral Radiol Endod*, 112 : e48-e55
6. Sasaki T, Imai Y, Fujibayashi T. (2001). A case of elongated pterygoidhamulus syndrome. *Oral Dis* 2001;7:131
7. Hjørtting-Hansen E, Lous I. (1987). The Pterygoid Hamulus syndrome. *Ugeskr Laeger*;6:979-82.
8. Naidoo S, Roode GJ, Bütow KW. (2014). Palatal pain due to *exostosis* of the posterior palatal spine in a cleft patient. *J Cleft Lip Palate Craniofacial Anatomy*. 11:124-126
9. Papadopoulos M, Jannowitz C, Boettcher P, Henke J, Stolla R, Zeilhofer H, et al. (2005). Three-dimensional fetal cephalometry: an evaluation of the reliability of cephalometric measurements based on three-dimensional CT reconstructions and on dry skulls of sheep fetuses. *JCraniomaxillofac Surg*;33:229-37.
10. Ngan DC, Kharbanda OP, Geenty JP, Darendeliler MA. Comparison of radiation levels from computed tomography and conventional dental radiographs. *Aust Orthod J* 2003;19:67-75.
11. Kumar V, Ludlow JB, Mol A, Cevidanes L. Comparison of conventional and cone beam CT synthesized cephalograms. *Dentomaxillofac Radiol* 2007;36:263-9
12. Gores RJ. Pain due to long hamular process in the edentulous patient. *Lancet* 1964;84:353-54
13. A.P.Sattu, K.N.Burde, M.Goyal, V.G.Naikmasur. Unusual cause of palatal pain. *Japanese Society for Oral and Maxillofacial Radiology and Springer* 2010;27:60-63
14. Kronman JH, Padamsee M, Norris LH. Bursitis of the tensor veli palatini muscle with an osteophyte on the Pterygoid Hamulus. *Oral Surg Oral Med Oral Pathol* 1991;71:420-2.
15. Salins PC, Bursitis BGP. A factor in the differential diagnosis of orofacial neuralgias and myofascial pain dysfunction syndrome. *Oral Surg Oral Med Oral Pathol* 1989;68:154-7
16. Fu Y, Peng J, Chen W. The Pterygoid Hamulus syndrome with the main discomfort of pharynx. *Lin Chuang Er Bi Yan Hou Ke Za Zhi* 2004;18:134-5.
17. Charbeneau TD, Blanton PL. The Pterygoid Hamulus. A consideration in the diagnosis of posterior palatal lesions. *Oral Surg Oral Med Oral Pathol* 1981;52: 574-6. 18. Ramirez LM, Ballesteros LE, Sandoval GP. Hamular bursitis and its possible craniofacial referred symptomatology: two case reports.
18. Shankland WE 2nd. Pterygoid hamulus bursitis: One cause of craniofacial pain. *J Prosthet dent* 1996;75:205-10.
19. Shankland WE 2nd. Bursitis of the hamular process. Part I: anatomical and histological evidence. *Cranio* 1996;14:186-9.
20. Shankland WE 2nd. Bursitis of the hamular process. Part II: diagnosis, 8. treatment and report of three case studies. *Cranio* 1996;14:306-11.

21. Curtin HD, Som PM, Braun FI, Nadel L. Skull base. In: SomPM, Curtin HD, editors. (1996). Head and neck imaging. 3rd ed. St.Louis: Mosby; . p. 1250
22. Baumrind S, Frantz RC. (1971). The reliability of head film measurements.2. Conventional angular and linear measures. Am J Orthod;60:505-17.
23. Sandler PJ. (1988). Reproducibility of cephalometric measurements. Br J Orthod ;15:105-10.
24. Kragkov J, Bosch C, Gyldensted C, Sindet-Pedersen S. (1997). Comparison of the reliability of craniofacial anatomic landmarks based on cephalometric radiographs and three-dimensional CTscans. Cleft Palate Craniofac J ;34:111-6.
25. Scaf G, Lurie AG, Mosier KM, Kantor ML, Ramsby GR, Freedman M L, et al. Dosimeter and cost of imaging osseointegrated implants with film-based and computed tomography. Oral SurgOral Med Oral Pathol Oral Radiol Endod 1997;83:41-8.
26. Hilgers ML, Scarfe WC, Scheetz JP, Farman AG. (2005). Accuracy of linear temporo-mandibular joint measurements with cone beam computed tomography and digital cephalometric radiography. Am J Orthod Dentofac Orthop ;128:803-11.
27. Moreira CR, Sales MA, Lopes PM, Cavalcanti MG. (2009). Assessment of linear and angular measurements on three-dimensional cone beam computed tomographic images. Oral Surg Oral Med Oral Pathol Oral Radiol Endod 2009;108:430-6
28. Farman AG, Scarfe WC. (2006). Development of imaging selection criteria and procedures should precede cephalometric assessment with cone-beam computed tomography. Am J Orthod Dentofac Orthop 2006;130:257-65.
29. Brown AA, Scarfe WC, Scheetz JP, Silveira AM, Farman (2009). A Linear accuracy of cone beam CT derived 3D images. Angle Orthod;79:150-7.
30. Mozzo P, Procacci C, Tacconi A, Martini PT, Bergamo IA. (1998). A new volumetric CT machine for dental imaging based on the cone-beam technique: preliminary results. Eur Radiol;8:1558-64.
31. White Sc, Pharoah MJ. (2014). Oral Radiology, Principles and Interpretation . 7th ed. St. Louis : Mosby Elsevier, 633-635

CITATION OF THIS ARTICLE

Mehri K, Roshanak G, Maryam A. Morphological Evaluation of Pterygoid Hamulus through Cone- Beam Computed Tomography Images. Bull. Env. Pharmacol. Life Sci., Vol 4 [2] January 2015: 144-150