



Effect of Induced Lead Intoxication on Histopathological Without or With Various Antioxidants in Broiler Chicken

Ritesh Jaiswal¹, S.L. Ali¹, S. Roy¹, S. Sakya¹, O.P Dinani¹, Sudhir Kumar Jaiswal^{2*}

¹College of Veterinary Science and A.H. Anjora, Durg, Chhattisgarh-(491 001), India

²Division of Poultry Science, Indian Veterinary Research Institute, Izatnagar, Bareilly, Uttar Pradesh- (243 122), India

*E-mail: sjsudhirjaiswal009@gmail.com

ABSTRACT

*In the present study effect of lead intoxication on histopathology of broiler chicken has been done. The birds were divided into six groups viz. A, B, C, D, E and F. Group-A served as control where as group-B received lead acetate @ 200 mg/kg basal diet for 42 days simultaneously Ascorbic acid @ 200 mg/kg basal diet, Vitamin-E @ 100/mg/kg and Se @ 0.1 mg/kg basal diet, DL-methionine @ 100 mg/ kg and methanolic extract of *Cissus quadrangularis* (CQE) @ 400 mg/kg basal diet were given to group B, C, D, E and F respectively. Histopathological changes showed necrotic foci and congestion of liver, kidney and spleen, haemorrhages on muscles, gizzard lining and intestinal wall, splenomegaly, hepatomegaly, enlarged kidney and bile stasis in lead exposed bird as compared to normal birds while other treatment groups showed very less to absence of signs. The liver, kidney, muscles, lung, and spleen showed distortion of cellular architecture in lead treated birds as compared to healthy control birds which had normal cellular architecture. Very few changes were recorded in other treatment groups. In the treatment groups section of muscles showed varying amount of fiber formation indicative of regeneration of damaged tissues against lead induced damages. Most pronounced regeneration activity was seen in group-C followed by group-D, group-E and F.*

Keywords: Lead, antioxidant, histopathology, chicken.

Received 17.12.2016

Revised 15.01.2017

Accepted 13.02.2017

INTRODUCTION

Lead is one of the most abundant heavy metal pollutants in the environment, and is well recognized as the most dangerous and insidious poisons [1]. However, both occupational and environmental exposures remains a serious problem in many developing and industrializing countries causes health problems in man and its contingent including animals [2]. Chronic exposure to Pb results in its accumulation, mainly in the feather, liver, kidneys, and brain, as well as in other organs and tissues, where it causes many metabolic and histological changes, membrane damage, altered gene expression, and apoptosis [3][4]. The aim of the present study is to evaluate the effect of induced lead intoxication on histopathological without or with various antioxidants in broiler chicken.

MATERIALS AND METHODS

The experiment was in accordance with animal welfare, and conducted under the protocols of Veterinary faculty, Anjora, Durg (Chhattisgarh) with the approval of Institutional Animal Ethics Committee (IAEC). For present study a total of 126 day old broiler chicks a of (Ven-Cobb strain) either sex along with broiler feed were procured from a well organized private hatchery of Indian Broiler Group, Rajnandgaon, Chhattisgarh. The diets were formulated according to the broiler chicken requirements suggested by the National Research Council guidelines (NRC, 1994).

Induction of lead intoxication and their treatment

All treatments were given to chicks on the basis of per kg basal diet daily for the period of 42 days. In this small amounts of basal diet was first mixed with the respective amounts of lead acetate @ 200 mg/kg to induce lead toxicity and with treatment drugs viz. ascorbic acid @ 200 mg/kg, Vit-E @ 100 mg/kg and Se @ 0.1 mg/kg, DL-methionine @ 100 mg/ kg and methanolic extract of *Cissus quadrangularis* powder @ 400 mg/kg as per treatment groups in a small batch. Then it was mixed with a larger amount of basal diet, until the total amount of respective diets were homogeneously mixed and was treated as per the experimental design (Table no.1)

Table1. Experimental design

Groups	No. of birds	Treatment given on the basis of per kg basal diet
A	21	Basal diet
B	21	Lead acetate @ 200 mg/kg
C	21	LEAD ACETATE @ 200 MG/KG + ASCORBIC ACID @ 200 MG/KG
D	21	Lead acetate @ 200mg/kg + Vit-E @ 100 mg/kg and Se @ 0.1 mg/kg
E	21	Lead acetate @ 200 mg/kg + DL-methionine @ 100 mg/ kg
F	21	Lead acetate @ 200 mg/kg + Methanolic extract of <i>Cissus quadrangularis</i> (CQE) @ 400 mg/kg

Histopathology

Histopathology of liver, kidney, muscles, lung, heart and spleen (Table no.2) of broiler chicken were performed at the end of experiment to assess the microscopic changes occurred due to lead exposure following standard technique of [5].

RESULTS AND DISCUSSION

Histopathological changes

Tissues of liver, kidney, muscles, lung, and spleen were collected from three birds of each group to study the histopathological changes due to lead induced intoxication and its comparison with control and different treatment groups of birds.

Liver

Histopathological examination of liver sections from control birds (group A) revealed well formed lobular structure and normal hepatic parenchyma with prominent parenchymatous cells. Section of liver from birds of lead treated group B (Fig.1 and 2) revealed congestion, haemorrhages, cloudy swelling, coagulative necrosis, massive fatty degeneration and serous exudation. At few areas the hepatic cells showed complete degeneration of hepatic cells along with dilated central vein and infiltrations of RBC's in central vein. The haemosiderosis was also evident. Liver section of birds of group C showed presence of inflammatory cells along with few RBCs and serous exudates. Mild fatty degeneration was also evident with no any other alterations. Liver section of group D showed mild coagulative necrosis only, no any other changes were observed. In group E, liver section showed black pigmentation with mild fatty degeneration only. Histopathology of group F liver revealed no any microscopic changes except presence of few fibrous tissues were present. [6] reported similar histopathological lesions like hepatocellular necrosis, and hemosiderosis in some avian species. [7] reported in broilers after administration of 400 ppm lead acetate in drinking water and diet. These hepatic lesions in lead treated birds could be possibly due to direct toxic effect of lead stimulating the intercellular signaling between kuffer cells and hepatocyte, there by promoting the proteolytic activities and damage the liver. Low grade changes in birds might be due to disturbances of normal biochemical processes of hepatobiliary system caused by low concentration of lead [7]. Liver is the central organ for all metabolic process, due to major role in the processing of foods and xenobiotics in the body, significant amount of toxic lead being absorbed and deposited in liver so the possible reason for lead damages in the cells are primarily through its ability to substitute for several metal ions, especially calcium and zinc, at their binding sites [8]. Lead produces oxidative damage to lipids and proteins as a result of iron release, disruption of antioxidant mechanisms, and direct oxidative damage [8] that was possibly reverted by various antioxidants used in the present study.

Kidney

Sections of kidney in control group (A) birds appeared normal with well formed tubular and glomerular structures. Histopathological examination of kidney of group B (Fig.-3 and 4) showed pronounced cloudy swelling, coagulative necrosis, degeneration and atrophy of proximal convoluted tubule (PCT) and bowman's capsules. The vacuolated cytoplasm and haemorrhages in glomeruli was also seen. Kidney section of group C birds showed milder degree of serous exudation and cloudy swelling and kidney of group D revealed mild cloudy swelling, similarly in group E kidney showed mild cloudy swelling but no cytoplasmic vacuolation and glomeruli were larger than the section of kidney of group B. In group F vacuolated cytoplasm and others alterations were nil to very mild in kidney. Present findings are in agreement of those reported by [9] and [10]. Kidney nephrosis consisted of degeneration and necrosis. [11] also observed necrosis of epithelium of proximal convoluted tubules of kidney and electron microscope revealed these cells containing irregular shaped electron dense inclusions of different size in lead poisoned chicks fed lead acetate at dose level of 5000 or 1000 ppm diet. [12] studied the effect of chronic lead ingestion (lead acetate @ 100 µg/ml drinking water for 90 days) and nephropathy in ringed turtledoves. They observed cell necrosis and intranuclear inclusion bodies in the PCT of kidney which supports the finding of the present study. In present study although mild histopathological alterations was observed in other treatment groups but they were lesser than lead treated group. The possible reason may be both due to antioxidative activity of vitamin-C and Vitamin-E or antagonistic nature of selenium, methionine and calcium, which might have decreased the lead burden in the kidney tissues due to enhancing the excretion of lead.

Muscles

Histopathological examination of muscles of negative control group (group-A) birds showed normal muscles fibers and architecture. Muscles section of lead treated group (group B) revealed (Fig.-5 and 6) loss of striation and necrosis of muscles fibers with massive haemorrhages between the muscles fibres. Group C muscles section showed more fibrous tissues in between the muscles fibers and group-D, E and F also had fewer fibrous tissues but muscles section of group E showed fibrinous exudates. Previous studies indicated that necrosis of ventriculus muscles [13] and hemosiderosis was a common histopathologic finding in some avian species [14]. This may be secondary to intravascular hemolysis or impairment of heme synthesis [14]. There are no evident reports on occurrence of haemorrhages in the other muscles tissues but it may be assumed that due accumulation of lead in muscles and its damaging potential of cell might have led to haemorrhages and loss of striations. The formation of fibrous tissue through regeneration of muscles fibres as evident in the present study might be due to the protective effect of various antioxidant used in lead exposed birds. In the present study most pronounced regeneration activity was seen in group C and group-D than the group E and F.

Lung

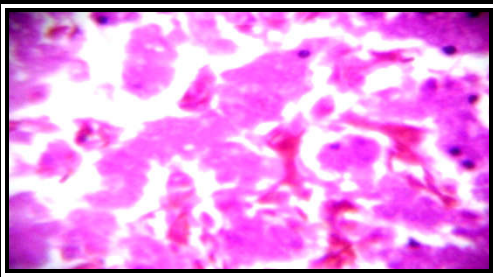
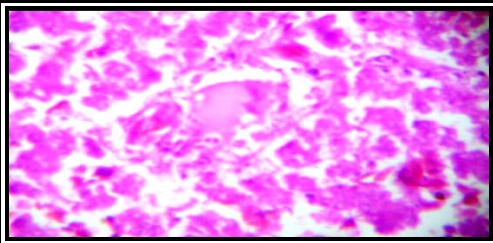
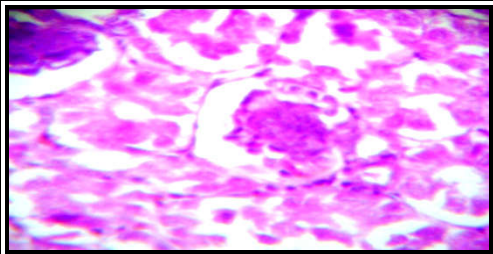
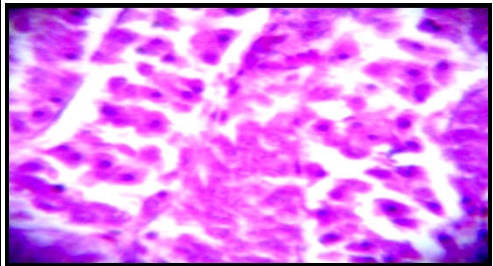
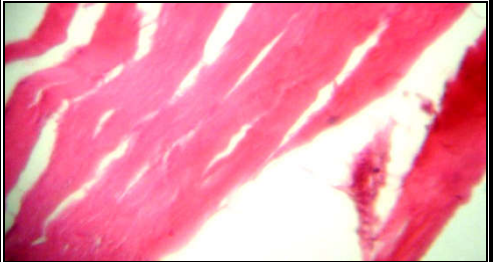
Sections of lung in the birds of control group showed normal bronchii, alveoli with well formed structures. In contrast histopathology of lung tissue of group B showed (Fig.-7 and 8) degeneration, bronchopneumonia, pneumonia between the alveoli, haemorrhages, haemosiderosis and RBCs. Thickened alveoli wall due to accumulation of serofibrinous exudates inside the alveoli was also evident. More or less similar findings were also observed in group C, D, E and F, although group D showed presence of serous fluid and group E showed interstitial pneumonia. [15] reported lead toxicosis in buffaloes and cattle in Punjab. Microscopic examination of lung showed intra-alveolar capillaries in the lungs, hyperaemic connective tissue. Septa were thickened and peribronchial mononuclear cell infiltration was seen. No precise reports are available in respect to lung histopathology of poultry due lead intoxication. The findings of present study showed that lead might reached to lung tissue level through blood circulation and possibly caused pathological alteration in the lung. Although severity of microscopic lesions were less in other treatment groups than the lead treated group, which might be due to cell protecting nature of various antioxidant against oxidative damage of cells from lead.

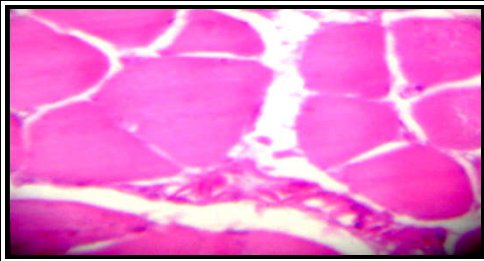
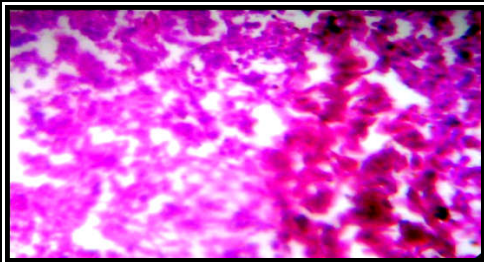
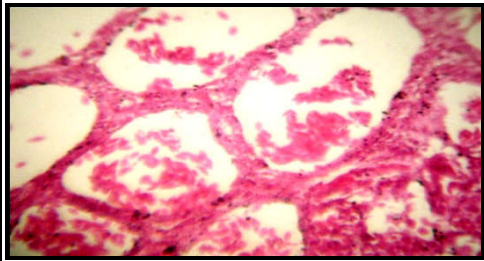
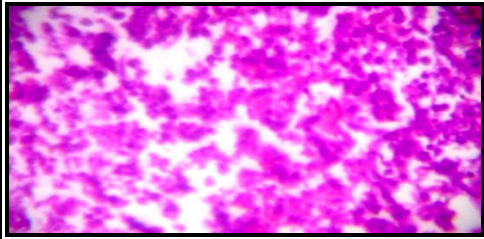
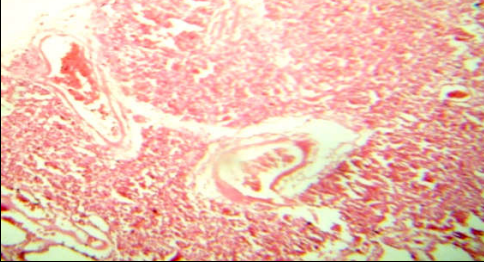
Spleen

Histopathological examination of spleen from group B birds revealed (Fig.-9 and 10) degeneration and necrosis of the lymphoid follicles, infiltration of lymphocytes and RBCs and vacuolated lymphoid cells as compared to control group A which showed normal structures of spleen. Histopathological findings of spleen of group C birds showed less degeneration and necrosis of lymphoid follicles as compared to lead treated group B.

Histopathology of spleen of birds of group D and E revealed similar findings to that of lead treated group B, however these changes were less pronounced. Group D also revealed degenerated red pulp or follicles while group F showed normal lymphocytes and very minute haemorrhages than the group B. The findings of [16] and [10] are conformity with the findings of the present study further it has been suggested that erythrocytes carry maximum lead burden of the blood and spleen is the site of erythrocyte fate thus possibly it could be the reason of pathological alteration of spleen[17].

Table 2. Showing figure of different organs and histopathological changes (H & E x 400).

Figure No.	Organ	Histopathological Changes	Figure
1.	Liver	Section of the liver showing cloudy swelling, degeneration, fatty degeneration and haemorrhages.	
2.	Liver	Section of the liver showing cloudy swelling, degeneration, Fatty degeneration, haemorrhages and serous exudates.	
3.	Kidney	Section of the kidney showing coagulative necrosis and atrophy of the glomeruli.	
4.	Kidney	Section of the kidney showing cloudy swelling and degeneration of tubules.	
5.	Muscle	Section of the muscle showing degeneration, haemorrhages and loss of striations.	

6.	Muscle	Section of the muscle showing degeneration and haemorrhages.	
7.	Lung	Section of the lung showing degeneration and haemorrhages.	
8.	Lung	Section of the lung showing degeneration, haemorrhages and alveoli filled with RBCs.	
9.	Spleen	Section of spleen showing haemorrhage and degeneration of the lymphoid follicles.	
10.	Spleen	Section of the spleen showing haemorrhage, degeneration of lymphoid follicles and necrosis of red & white pulp.	

CONCLUSION

Lead supplementation in diet resulted in alteration of normal structure of various tissues. Histopathological changes of variable degree in various organs viz. liver, kidney, muscles, lungs and spleen were also evident.

ACKNOWLEDGEMENT

IB Group, Rajnandgaon, Chhattisgarh for providing free of cost Ven-Cobb strain broiler chicks; Dean, Veterinary College Anjora, Durg (Chhattisgarh) for providing necessary facilities and Head, Department of Animal Nutrition for feed formulation.

REFERENCES

1. White, L.D., Cory-Slechta, D.A. & Gilbert, M.E. (2007). New and evolving concepts in the neurotoxicology of lead. *Toxicol. Appl. Pharmacol.*, 225:1-27.
2. Gurer, H. & Ercal, N. (2000). Can antioxidants be beneficial in the treatment of lead poisoning? *Free Radical., Bio. Med.*, 29: 927-945.

3. Kojima, M., Nemoto, K. & Murai, U. (2002). Altered gene expression of hepatic lanosterol 14α-demethylase (CYP51) in lead nitrate-treated rats. *Arch Toxicol.*, 76:398–403.
4. Sobin, C., Montoya, M.G. & Parisi, N. (2013). Microglial disruption in young mice with early chronic lead exposure. *Toxicol. Lett.*, 220:44–52.
5. Lillie, R.D. (1965). *Histopathological technique and practical histochemistry*. New York, USA. The Blackinton Co. Inc.
6. Puschner, B. & Robert, H.P. (2009). Lead and Zinc intoxication in companion birds. *Compendium*, 31(1). University of California, Davis.
7. Sipos, P., Szentmihályi, K., Feher, E., Abaza, M. & Szilágyi, M. (2003). Some effect of lead contamination on liver and gall bladder bile. *Acta. Biol. Szeged.*, 47 (1-4): 139-142.
8. Garza, A., Vega, R. & Soto, E. (2006). Cellular mechanisms of lead neurotoxicity. *Med. Sci. Monit.*, 2: 57-65.
9. Brar, R.S. (1994). Studies on clinicopathological, biochemical and histoenzymological alterations in lead toxicosis in domestic fowl and buffalo calves. *Ind. J. Vet. Pathol.*, 18(1): 69-79.
10. Chauhan, R.S., Khurana S.K. & Mahipal, S.K. (1995). Pathology of chronic lead poisoning in chickens. *Ind. J. Toxicol.*, 2: 56.
11. Simpson, C.F., Damron, B. L. & Harms R.H. (1970). Abnormalities of erythrocytes and renal tubules of chicks poisoned with lead. *Am. J. Vet. Res.*, 31: 515-523.
12. Kendall, R.J. & Scalon, P.F. (1981). Chronic lead ingestion and nephropathy in ringed turtle doves. *Poult. Sci.*, 60: 2028-2032.
13. Gwaltney-Brant, S. (2004). Lead In: Plumlee, K.H., ed. *Clinical Veterinary Toxicology*. St. Louis, Mosby., 204-210.
14. Mateo, R., Beyer, W.N. & Spann, J.W. (2003). Relation of fatty acid composition in lead-exposed mallards to fat mobilization, lipid peroxidation and alkaline phosphatase activity. *Comp. Biochem. Physiol. Toxicol. Pharmacol.*, 135: 451-458.
15. Youssef, S.A.H., Sanousi, A.A., Afifi, N.A. & Brawy, A.L. (1996). Effect of subclinical toxicity on the immune response of chicken to New Castle Disease Virus Vaccine. *Research Vet. Sci.*, 60: 13-16.
16. Garg, S. K. (2000). Toxicity of Metals. In: *Veterinary Toxicology*. Edn Ist., CBS Publishers and Distributors, New Delhi., pp 42-47.

CITATION OF THIS ARTICLE

R Jaiswal, S.L. Ali, S. Roy, S. Sakya, O.P Dinani, S K Jaiswal. Effect of Induced Lead Intoxication on Histopathological Without or With Various Antioxidants in Broiler Chicken. *Bull. Env. Pharmacol. Life Sci.*, Vol 6[4] March 2017: 63-68