



SARS CoV-2 as an Etiological Risk factor in the Evolution of essential tremor on Parkinson's Disease and optimization of Therapeutic approaches

***Nargiza Eshankulova, Rano Azizova, Kalandarova Sevara**

Department of Neurology, Tashkent Medical Academy, Uzbekistan

*<https://orcid.org/0009-0004-6775-9326>

**<https://orcid.org/0000-0002-3644-8638>

ABSTRACT

In 2019, there are several scientific works showing that the acute respiratory syndrome coronavirus (SARS CoV-2) was one of the main factors in the manifestation of several diseases as the causative agent of a cluster of respiratory infections. There are also reports of increased tremors, bradykinesia, and gait disturbances in patients with movement disorders, including Parkinson's disease, after COVID-19. It should be considered that SARS CoV-2 may also play a role in the evolution of essential tremor into Parkinson's disease. When essential tremor transforms into Parkinson's disease, the disease differs from classic Parkinson's disease. In addition, when essential tremor and Parkinson's disease occur in a comorbid condition, treatment effectiveness may increase if treatment tactics are focused on both nosologies.

Key words: SARS CoV-2, Parkinson's disease, essential tremor, DBS

Received 06.06.2023

Revised 05.08.2023

Accepted 21.08.2023

INTRODUCTION

Essential tremor (ET) is one of the most common causes of tremor in neurological disorders. However, there is a lot of scientific work being done [1] on the association with Parkinson's disease (PD).

Several studies have reported that patients with young-onset asymmetric ET later developed the resting tremor characteristic of PD on this side [2,3]. Although we know that movement-dependent tremor in ET is characterized by tremor in a resting state, but tremor in a resting state is characteristic of PD, but it is well known that two types of tremor occur in both diseases, and that there are symptoms that hide and confuse each other in diagnosis, that is, tremor in both movement and at rest, PD in family history or The presence of ET, symptoms of mild dopamine deficiency [4,5]. In addition to tremors, bradykinesia, rigidity (only in the form of a cogwheel), body balance, and nonmotor signs can also be observed in ET. Evidence of this is the positive response to levodopa of head tremors and voice changes characteristic of ET. Jaw tremor is usually characteristic of PK. Usually, strong tremors in the head and legs are observed only when PD is accompanied by ET [6].

A high frequency of ET was observed in patients with tremor-dominant form of PD when family history was collected [7]. Studies have shown that dopamine deficiency in ET is associated with dopamine production in the caudate nucleus, while dopamine deficiency in PD is associated with neuronal death in the putamen and substantia nigra [12].

Despite the fact that ET is a common disease, no specific gene has been found to be responsible for the disease, but in PD there are several of these genes [13].

The transfer of ET to PD occurs due to Lewy bodies [9], which means that cerebrospinal tracts and Purkinje cells are damaged as a result of exposure to several neurotoxins. Trigger factors include post-traumatic stress disorders [10], various infectious diseases, namely SARS CoV-2 in the COVID 19 pandemic [11].

Although several convincing lines of evidence support the evolution of essential tremor into Parkinson's disease, the biological nature of the link between these disorders is not fully understood. In addition, it is not known exactly which factors predict the subsequent transition of ET to PD.

In 2019, severe acute respiratory syndrome coronavirus (SARS CoV-2) was identified as the causative agent of a cluster of respiratory infections and later named coronavirus disease 2019 (COVID-19) [14]. There are

several studies showing an increase in symptoms such as tremor, bradykinesia, and gait disturbances in patients with movement disorders, including Parkinson's disease, after COVID 19 [15,16]. This article presents a study and conclusions about the possibility of SARS-CoV-2 being a putative mechanism in the transition of ET to PD during the COVID-19 pandemic.

MATERIAL AND METHODS

The patient was examined and treated at the Department of Neurology of Tashkent Medical Academy and Istanbul Medipol Mega University. The following instrumental examinations, tests and procedures were performed on the patient. A brain magnetic resonance imaging (MRI) performed in april 2022. The patient's tremor status from 2019 to 2022 was compared 2019 (T1), 2021 (T2), 2022 (T3). Disorder Society Unified Parkinson's Disease Rating Scale (MDS-UPSRD), Hamilton Anxiety Rating Scale (HAM-A); Hamilton Depression Rating Scale (HAM-D) Mini-Mental State Examination (MMSE) evaluated by standardized scales. Medication and deep brain stimulation (DBS) surgery treatments with Boston Scientific's Deep Brain Stimulation system electrodes were applied to the patient.

CLINICAL CONDITION

Patient A., 34 years old. According to the patient, he had a slight tremor in his left hand since he was 16-17 years old. Tremors have been observed to increase during excitement and nervousness. His maternal grandfather had Parkinson's disease in his family history. No bad habits. His childhood and adolescence were spent in good conditions. At the age of 27, he noticed an increase in tremors and began to interfere with his daily activities. At the age of 28, he consulted a neurologist for the first time and was diagnosed with essential tremor. Non-selective beta-blocker (propranolol) is recommended to drink half a tablet of 40 mg. Tremor has decreased against the background of the drug. There was also a positive response to alcohol. During the 2020 COVID-19 pandemic, a SARS-CoV-2 polymerase chain reaction (PCR) test was positive in May. The patient had only anosmia symptoms, no other symptoms of SARS-CoV-2 infection were observed. By the autumn of 2020, the patient noticed that tremors appeared even when he was resting. In addition, he noticed heaviness and pain in the muscles of his left hand, slowness of movements. Increased the amount of non-selective β -blocker (propranolol) to 1 whole tablet. But the above signs have not decreased. In December 2020, he consults another neurologist and is diagnosed with Parkinson's disease for the first time, and is prescribed Nakom 250/25 mg (levodopa/carbidopa) ¼ tablet 4 times a day. Against the background of the drug Nakom 250/25 mg, muscle pain decreases, slowness of movements decreases. In April 2021, he referred to us with an increase in the above complaints and the appearance of tremors in the left leg.

The state of the neurostatus at the time of contacting us. Hypoosmia in the first pair of cranial nerves (nervus olfactorius), slight tremor in the tongue and lower jaw, and hypomimia in the face were detected. The rest of the cranial nerves are unchanged. There are no paresis. Active movements are full, there is a slowdown in the movement of the left limbs. Muscle tone increased plastically in the left arm and left leg. A "cog wheel" symptom is positive in the joints of the left hand. Resting and kinetic tremors are detected in the left arm and left leg. Tendon reflexes are evoked BR,PR,AR,TR normally D=S. Pathological reflexes are not detected. The sphere of perception is unchanged. Romberg test not sway in the pose. From the locomotor tests, the finger-nose test is performed with intention in the left hand. The activity of the pelvic organs is unchanged. Meningeal signs are negative.

Higher nervous activity: Mini Mental State Examination (MMSE) scale 28 points. The Beck Anxiety Scale (BAI) was used to diagnose anxiety and the patient's score was 23 (moderate anxiety disorder). The Hamilton scale was used to determine the level of depression (19 points moderate depression). Pittsburgh Sleep Disorders Scale (PSQI) 4 points no sleep disorder. Parkinson's disease unified rating scale of the international movement disorder society MDS-UPDRS I, II, III parts, according to the result UPDRS I - 1.6 UPDRS II - 9.82 UPDRS III - 19.56. indicators were obtained.

For comparison, the state of tremors for three years 2019 T1-2021 T2-2023 T3.(fig.1.)

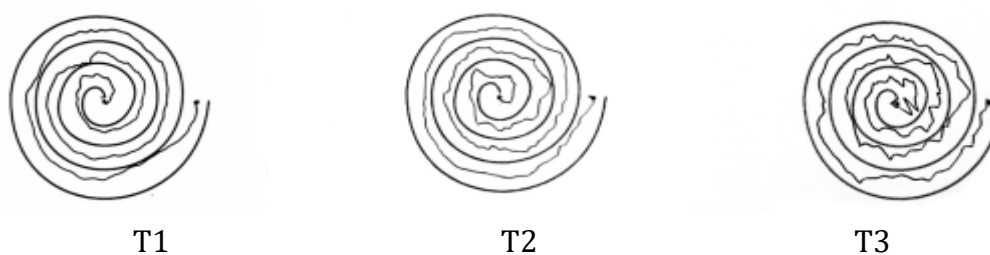


Figure 1. tremors for three years 2019 T1-2021 T2-2023 T3

A patient was diagnosed: Parkinson's disease of tremor dominant form. Second stage on the Hoehn and Yahr.

Brain MRI summary (2022). Deformations and destructive changes were not detected in the brain. Moderate atrophy of frontal-temporal lobes.(fig.2.).

The patient was ordered to drink 1 tablet of Nakom 250/25 mg (levodopa/carbidopa) 4 times a day. PK Merz 100 mg (amantadine sulfate) tablet was prescribed 1 tablet 1 time, neuromultivit 2.0 ml intramuscularly for 10 days. After increasing the dose of the drug, the patient began to have involuntary movements in the body, and Nakom was again reduced to ½ tablet. Taking into account that these complaints have a significant negative impact on the patient's quality of life and increased tremor and rigidity, dyskinesia when the drug dose is increased, the patient was recommended to perform Deep Brain Stimulation (DBS) with the help of electrodes. In 2022, the patient was examined at Istanbul Medipol University Hospital, Turkey with the help of Turkish doctors, and the patient was diagnosed with "Parkinson's disease with essential tremor".

After the results of all laboratory and instrumental examinations, no contraindication to the operation was found, and a Deep Brain Stimulation (DBS) surgery was performed on 04.20.2022. Boston Scientific's Deep Brain Stimulation system electrodes were placed near the subthalamic nuclei (STN). The patient's clinical symptoms of Parkinson's disease after the procedure almost disappeared by the 10th day after the appropriate electrode settings. However, due to the preservation of positional tremor during movement in the left hand, non-selective β -blocker (Dideral) was prescribed ½ tablet.

Indications in the patient on the 30th day after treatment: Neurostatus. Cranial paired nerves (CPN): hyposmia in the first pair of nerves, slight tremor in the tongue, tremor in the lower jaw - absent, hypomimia in the face. The rest of the CPN are unchanged. There are no paresis. Active movements are in full swing. Muscle tone is normal. "Gear wheel" symptom is negative in all joints. Foot reflexes are evoked, normally. Pathological reflexes are not detected. The sphere of perception is unchanged. Romberg test does not sway in the pose. The locomotor performs the tests correctly. The activity of the pelvic organs is unchanged. Meningeal signs are negative.

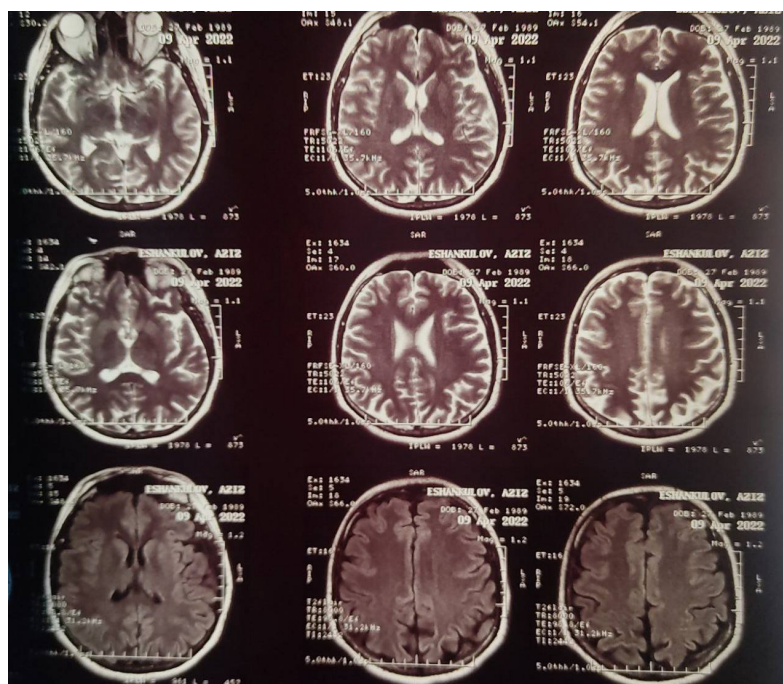


Figure 2. Deformations and destructive changes were not detected in the brain. Moderate atrophy of frontal-temporal lobes

Higher nervous activity: Mini Mental State Examination (MMSE) scale 28 points. The Beck Anxiety Scale (BAI) was used to diagnose anxiety and the patient had a score of 17 (mild anxiety disorder). The Hamilton scale was used to determine the level of depression (6-point norm). Pittsburgh Sleep Disorders Scale (PSQI) score of 3 is no sleep disorder. Parkinson's Disease Unified Rating Scale of the International Movement Disorder Society MDS-UPDRS UPDRS I - 1, UPDRS II - 2.62 UPDRS III - 2.36.

CONCLUSION

Conclusions from this clinical case further support the possibility that essential tremor may later progress to Parkinson's disease [2] and are consistent with data from other literature. It was considered that SARS CoV-2 infection may be one of the etiological factors in the transition from essential tremor to Parkinson's disease. When essential tremor passes to Parkinson's disease, the symptoms of ET do not disappear anywhere, and in conclusion, when choosing a treatment strategy, it is necessary to pay attention to the treatment of ET, not only levodopa drugs. Because ET-specific tremor that remains can cause anxiety and depression to worsen, creating a negative background in the patient's social life. It is also consistent with other scientific studies that Deep Brain Stimulation (DBS) surgery is the optimal solution for the early onset of dyskinesias in Parkinson's disease.

REFERENCES

1. C.H. Adler, H.A. Shill, T.G. Beach, (2011). Essential tremor and Parkinson's disease: lack of a link, *Mov. Disord.* 26; 372-377
2. J. Shahed, J. Jankovic, Exploring the relationship between essential tremor and Parkinson's disease, *Park. Relat. Disord.* 13 (2007) 67e76.
3. M.T. Minen, E.D. Louis, Emergence of Parkinson's disease in essential tremor: a study of the clinical correlates in 53 patients, *Mov. Disord.* 23 (2008) 1602e1605.
4. R. Fekete, J. Jankovic, Revisiting the relationship between essential tremor and Parkinson's disease, *Mov. Disord.* 26 (2011) 391e398.
5. M.A. Thenganatt, E.D. Louis, Distinguishing essential tremor from Parkinson's disease: bedside tests and laboratory evaluations, *Expert Rev. Neurother.* 12 (2012) 687e696.
6. O. Cohen, S. Pullman, E. Jurewicz, D. Watner, E.D. Louis, Rest tremor in patients with essential tremor: prevalence, clinical correlates, and electrophysiologic characteristics, *Arch. Neurol.* 60 (2003) 405e410.
7. W.A. Rocca, J.H. Bower, J.E. Ahlskog, A. Elbaz, B.R. Grossardt, S.K. McDonnell, D.J. Schaid, D.M. (2007). Maraganore, Increased risk of essential tremor in first-degree relatives of patients with Parkinson's disease, *Mov. Disord.* 22; 1607e1614.
8. Huang C, Wang Y, Li X, Ren L, Zhao J, Hu Y, et al. (2020). Clinical features of patients infected with 2019 novel coronavirus in Wuhan, China. *Lancet.*395:497–506
9. Louis ED, Vonsattel JP. (2008). The emerging neuropathology of essential tremor. *Mov Disord.* 30;23(2):174-82. doi: 10.1002/mds.21731. PMID: 17999421; PMCID: PMC2692583.
10. Barer Y, Chodick G, Glaser Chodick N, Gurevich T. (2022). Risk of Parkinson Disease Among Adults With vs Without Posttraumatic Stress Disorder. *JAMA Netw Open.* 2022 Aug 1;5(8):e2225445. doi: 10.1001/jamanetworkopen.2022.25445. PMID: 35925604; PMCID: PMC9353613.
11. Passaretti M, De Biase A, Paparella G, Angelini L, Cannavacciuolo A, Colella D, Berardelli A, Bologna M. Worsening of Essential Tremor After SARS-CoV-2 Infection. *Cerebellum.* 2023 Feb;22(1):155-158. doi: 10.1007/s12311-022-01366-8. Epub 2022 Jan 6. PMID: 34989982; PMCID: PMC8732967.
12. O. Waln, Y. Wu, R. Perlman, J. Wendt, A.K. Van, J. Jankovic, (2015). Dopamine transporter imaging in essential tremor with and without parkinsonian features, *J. Neural Transm.* 122(11) : doi: 10.1007/s00702-015-1419-z.
13. H. Unal Gulsuner, S. Gulsuner, F.N. Mercan, O.E. Onat, T. Walsh, H. Shahin, M.K. Lee, O. Dogu, T. Kansu, H. Topaloglu, B. Elibol, C. Akbostanci, M.C. King, T. Ozelik, A.B. Tekinay, (2014). Mitochondrial serine protease HTRA2 p.G399S in a kindred with essential tremor and Parkinson disease, *Proc. Natl. Acad. Sci. U. S. A.* 111; 18285e18290.
14. Huang C, Wang Y, Li X, Ren L, Zhao J, Hu Y, et al. (2020). Clinical features of patients infected with 2019 novel coronavirus in Wuhan, China. *Lancet.* 395:497–506
15. Scoppettuolo P, Borrelli S, Naeije G. (2020). Neurological involvement in SARS-CoV-2 infection: a clinical systematic review. *Brain Behav Immun Health.* 5:100094.
16. Xing F, Marsili L, Truong DD. (2021). Parkinsonism in viral, paraneoplastic, and autoimmune diseases. *J Neurol Sci.* 20014. <https://doi.org/10.1016/j.jns.2021.120014>.

CITATION OF THIS ARTICLE

Nargiza E, Rano A , Kalandarova S. SARS CoV-2 as an Etiological Risk factor in the Evolution of essential tremor on Parkinson's Disease and optimization of Therapeutic approaches. *Bull. Env. Pharmacol. Life Sci.*, Vol 12 [9] August 2023: 357-360