



## CASE STUDY

# Successful Endoscopic Removal of a Sewing needle in the Stomach of a Shih Tzu

**Hedieh Roshanzamir<sup>1</sup>, Soulmaz Naserli<sup>2</sup> & Bijan Ziaie<sup>3\*</sup>**

1. Founder, Azerbaijan Animal Rescue Center, Baku, Republic of Azerbaijan.
2. Department of Laboratory, Azerbaijan Animal Rescue Center, Baku, Republic of Azerbaijan.
3. Department of Internal Medicine, Azerbaijan Animal Rescue Center, Baku, Republic of Azerbaijan.

**\*Corresponding author: [b.ziaie@aacr.az](mailto:b.ziaie@aacr.az)**

## INTRODUCTION

Dogs and cats can eat some strange and crazy things! Though, Dogs tend to be repeat offenders more than cats. Therefore, one of the most common gastrointestinal (GI) disorders in pets is gastroenteritis due to foreign body having been swallowed such as needles, coins, chains, Lego pieces, jewelry, etc.

There are two ways to retrieve a gastrointestinal foreign body, a) Surgery and b) Endoscopy. Endoscopy requires general anesthesia, but it is often preferred over surgery because of its less invasive nature.

Fiber optic endoscopy (fig. 1) is a noninvasive technique for evaluating the lumen and mucosa of the gastrointestinal tract. It is a fundamental method for investigation of the digestive tract, and is important in the diagnosis and prognosis in a variety of GI disorders.



**Fig 1:** Flexible endoscopy

Endoscopy is used to take biopsies of organs, remove foreign objects, examining the interior surface of hollow structures, and perform procedures typically performed by more invasive surgery. Both rigid and flexible endoscopies are commonly used to remove foreign objects. This short communication is the first report for successful management of needle extraction from canine stomach by endoscopy procedure in The Republic of Azerbaijan.

## Case presentation

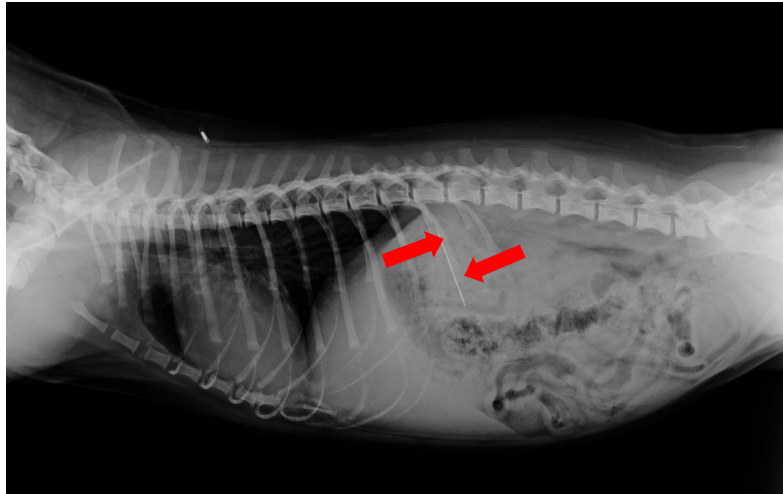
A one-year-old male Shih Tzu was referred to Azerbaijan Animal Rescue Center (AARC) hospital by a private veterinary clinic. The dog was taken to the first clinic for swallowing of a sewing needle by client complaint which diagnosed by plain abdominal radiography.

On presentation to AARC, the physical examination was unremarkable except intermittent vomiting, mild degree of lethargy and 5-6% dehydration.

Hematologic lab data demonstrated an inflammatory leukogram and mild degree of normocytic-normochromic anemia which could have been due to acute gastrointestinal bleeding. Other hematological

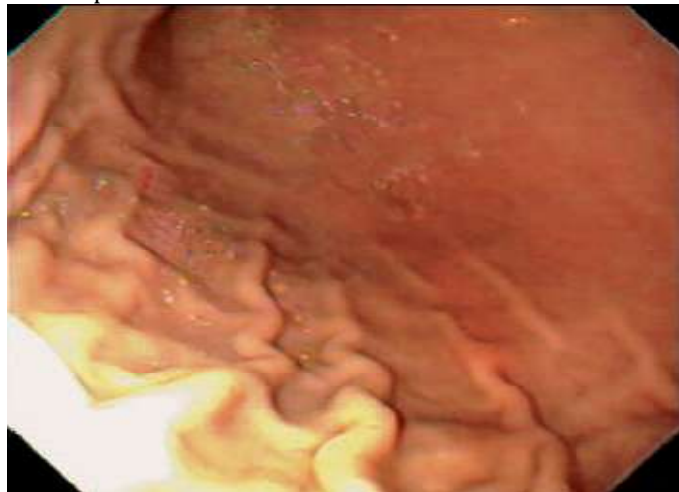factors, serum biochemical analysis and urinary analysis were within the normal range (Vet Lab Station, IDEXX, USA).

In plain radiographic study (FCR Capsula XLII, FUJIFILM, China), a needle was detected in the fundic region of patient's stomach (fig. 2).



**Fig 2:** The arrows show needle located in fundus of the stomach.

After confirmation by radiographic evaluation, general anesthesia induced with 5 mg/kg Ketamin and 1 mg/kg Xylazine combination. A cuffed endotracheal tube was located for prevention of idiopathic tracheal damage and minimization of aspiration.

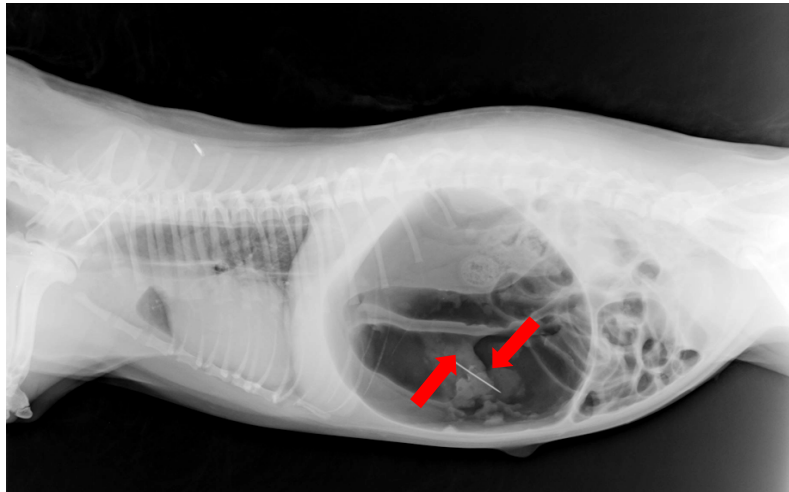


**Fig 3:** Endoscopic view of the patient's stomach.

The patient was placed in left lateral recumbency and the insertion tube of endoscope (AOHUA , China) was inserted to the esophagus gently.

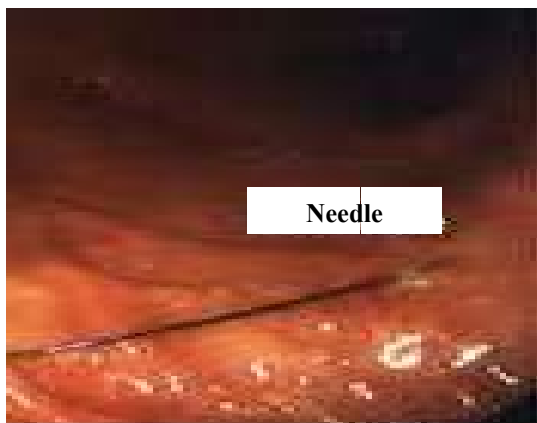
An endoscopic view of esophagus was completely normal but focal hemorrhages were detected in gastric view especially in fundus region (fig. 3). Finally after more evaluation a sewing needle was detected in gastric fundus which was covered with food and had entered the mucosa membrane.

Another plain radiographic evaluation was performed after controlled insufflations of the stomach. Sewing needle was extracted from gastric mucosa membrane due to extension of gastric wall (fig. 4 and fig. 5).

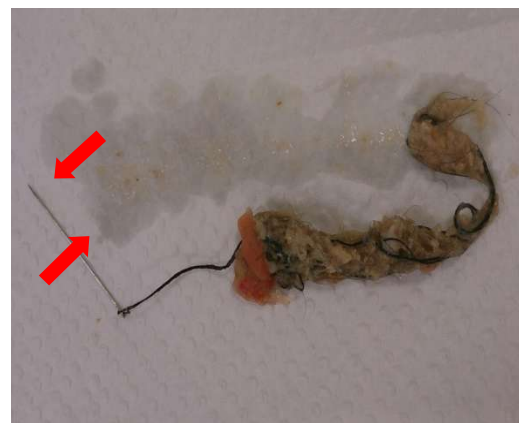

**Fig 4:** The arrows show needle after detachment from gastric mucosa membrane.

After this step, the insertion tube of endoscope was inserted in to the stomach and the 5 centimeter sewing needle which had been trapped in GI tract was successfully removed with an alligator forceps (fig. 6).



**5:** Endoscopic view of sewing needle.



**Fig**

**6:** the needle which removed from stomach.

In order to control stomach injury due to the sharpness of sewing needle, conservative treatment was performed followed by the complete general anesthesia recovery. The treatment protocol was as follows: NPO for 24 hrs, intravenous fluid therapy with Ringer, 20 mg/kg BID Cefazolin, 1 mg/kg BID Ranitidine and 0.5 mg/kg Metoclopramide for reducing the gastric acidity and faster healing. The patient recovered completely after 3 days of treatment.

#### **DISCUSSION AND CONCLUSION**

Foreign body swallowing is a common problem in pet gastrointestinal disorders especially in dogs. The most common foreign objects include coins, chains, toys, needles and jewelry. GI perforation due to some foreign objects allows leakage of non-sterile gastrointestinal contents into the abdominal cavity resulting in widespread inflammation (peritonitis). With emergency surgery and post-operative intensive care, many of these patients can survive and recover. Therefore, to prevent this situation the pet's owner must supervise their pet's behaviors carefully. There are two ways to retrieve a gastrointestinal foreign body: a) Surgery and b) Endoscopy.

Considering the tremendously advanced technology in imaging, endoscopy is a fundamental method and remains the most commonly used, cost effective, minimally invasive diagnostic tool in veterinary medicine for diagnosis and prognosis of a variety of gastrointestinal disorders such as esophagitis, hiatal hernia, acute and chronic gastritis, gastric ulceration, foreign body, neoplasia, colitis, cecal eversion, etc. As with any diagnostic tool, gastrointestinal endoscopy has both advantages and disadvantages that need to be considered.

The most important limitation of GI endoscopy, however, is the inability to biopsy the sub- mucosa, much less obtain full-thickness biopsies. Complications associated with gastrointestinal endoscopy are rare. Although endoscopy is considered to be a minimally invasive procedure, it does require general anesthesia. Organ perforation is a potentially catastrophic complication but is extremely rare. The most common endoscopic complication is a consequence of over distention of the stomach with insufflated air. This problem is prevented by vigilant awareness of the degree of gastric distention and close anesthetic monitoring.

Before performing upper gastrointestinal endoscopy, the patient must fast for at least 12 to 24 hours. This restriction is important because the presence of food in the stomach makes gastric evaluation almost impossible. It should be noted that patients with gastric disease often have altered motility, and a standard 12 hr fast may be insufficient. So, the huge difficulty in the referred Shih Tzu's case was having had food just 4 hrs before referring to AARC. For gastroenteritis due to foreign body, time is of critical importance. Quick referral to AARC was a positive point for this Shih Tzu.

This report is the first successful endoscopic removal of a sewing needle in the stomach of a canine in the Republic of Azerbaijan.

In conclusion, the best prevention for gastrointestinal foreign body is to monitor pet's behavior closely and keeping objects that can be swallowed by them out of their reach.

In such dramatic cases, for better gastric endoscopy evaluation and increasing the chance of successful extraction, off feeding and quick referral to veterinary medicine centers are recommended to the owners.

Note: Unfortunately, not all cases of foreign body ingestion have such happy endings, particularly if the foreign object has perforated through the wall of the stomach or intestinal loop.

#### REFERENCES

1. Ettinger S. J. and Feldman E. C. (2010). *Text book of Small Animal Internal Medicine*. Philadelphia: Elsevier Vol 2.
2. Fosum T. W. (2011). *Small Animal surgery*. Chapter 14; Principles of Minimally Invasive surgery. St Louis: Elsevier.
3. Lecoindre P. An atlas of gastrointestinal endoscopy in dogs and cats. *Waltham Focus* 1999; vol 9, n o 3.
4. Plumb D. C.(2008). *Veterinary Drug Handbook*. John wiley.
5. Simpson K. W. Gastrointestinal endoscopy in the dog. *Journal of Small Animal Practice* 1993; 34: 180–188.
6. Tams T. R. (1990). *Small Animal Endoscopy*. St Louis: The CV Mosby Company, 417.
7. Webb C. B. (2001). *Gastrointestinal endoscopy in dogs and cats*. The Gloyd Group, Inc.

#### CITATION OF THIS ARTICLE

Hedieh R, Soulmaz N & Bijan Z. Successful Endoscopic Removal of a Sewing needle in the Stomach of a Shih Tzu. *Bull. Env. Pharmacol. Life Sci.*, Vol 4 [5] April 2015: 170-173